

Radiology Corner, Case # 23

Traumatic Carotid Pseudoaneurysm Post Gun Shot Wound to the Head/Neck

Guarantor: CAPT Erik L. Abrames, USAF, MC ¹

Contributors: CAPT Erik L. Abrames, USAF, MC ¹; MAJ Stephen R Chen USAF, MC ²;
LT COL Wilmer Jones, USAF, MC ³; COL Les Folio, USAF, MC, SFS ⁴

Note: This is the full text version of the radiology corner question published in the April 2008 issue, with the abbreviated answer in the May 2008 issue.

Pseudoaneurysms have many etiologies that include blunt or penetrating trauma, iatrogenically during vascular procedures or dehiscence of a vascular graft. Pseudoaneurysms can be treated in a variety of ways and treatment decisions often depend on their size and location. In Iraq, a security guard was found to have a carotid pseudoaneurysm after sustaining a gun shot wound to the head and neck. The following discussion looks at causes, imaging modalities, and treatment options for pseudoaneurysms with additional focus on carotid pseudoaneurysms and the use of endovascular therapy in the deployed setting.

Introduction

Pseudoaneurysms can occur when the layers of an artery are disrupted and a hematoma forms within the periarterial tissues. The hematoma becomes a cavity of blood and thrombus and becomes a pseudoaneurysm if it communicates with the true vessel lumen. There are many etiologies, but pseudoaneurysms are primarily caused by anastomotic dehiscence, vascular procedures, and blunt or penetrating trauma. The majority occur at the common femoral artery and are the result of an arterial puncture. It has been estimated that the incidence of pseudoaneurysms is 0.05% to 0.4% of arterial punctures depending on the complexity of the procedure.¹

Small pseudoaneurysms can be asymptomatic, but symptoms can include pain, a pulsatile mass, and potential compression of adjacent nerve fibers. Low-grade fevers often are present with infected pseudoaneurysms. Three independent factors for the development of femoral pseudoaneurysms include female gender (smaller arteries which are more difficult to access), interventional procedures (larger-diameter sheaths compared to those used for diagnostic studies), and lack of a closure device (while decreasing the incidence of bleeding and number of pseudoaneurysms, closure devices are

associated with an increased number of thrombotic and infective complications).²

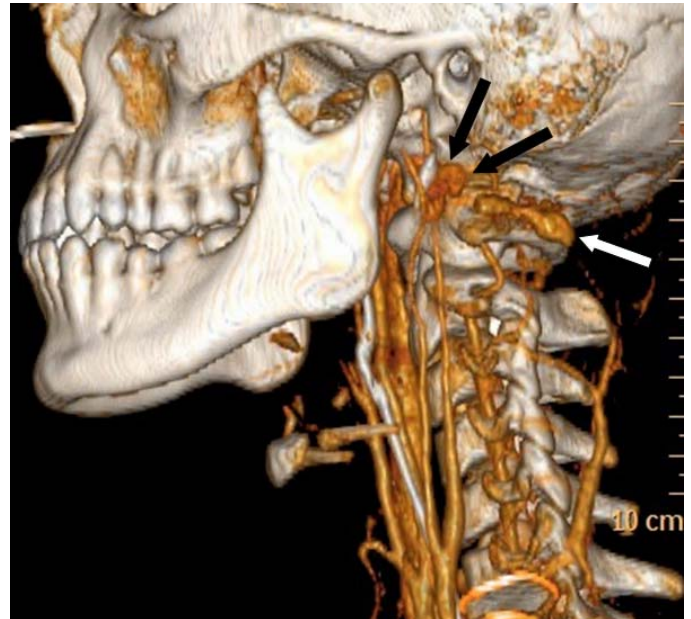

Fig. 1. Three dimensional reformatted image of CT Angiogram showing the internal carotid pseudoaneurysm (black arrows) and small vertebral pseudoaneurysm (white arrow).

While the majority of pseudoaneurysms occur at the femoral artery, they can develop in any artery including the internal carotid. Most Internal Carotid Artery (ICA) pseudoaneurysms are the result of blunt trauma. Sudden forceful hyperextension and lateral rotation of the head can cause stretching of the carotid artery over the cervical vertebra resulting in intimal injury. This can occur during motor vehicle accidents, but also fights, athletic events, clothesline injuries, and near hangings. In addition, ICA pseudoaneurysms can occur from complications during surgery, in particular transphenoidal surgery, but also primary and salvage neck surgery. Lastly, penetrating trauma such as gunshot wounds can result in ICA pseudoaneurysms.

¹ Misawa Air Force Medical Center, Japan.

² Wilford Hall Medical Center; San Antonio, TX

³ Wilford Hall Medical Center; San Antonio, TX

⁴ Department of Radiology and Radiological Sciences; Uniformed Services University of the Health Sciences, Bethesda, Maryland 20814-4799

Reprint & Copyright © by Association of Military Surgeons of U.S., 2006.

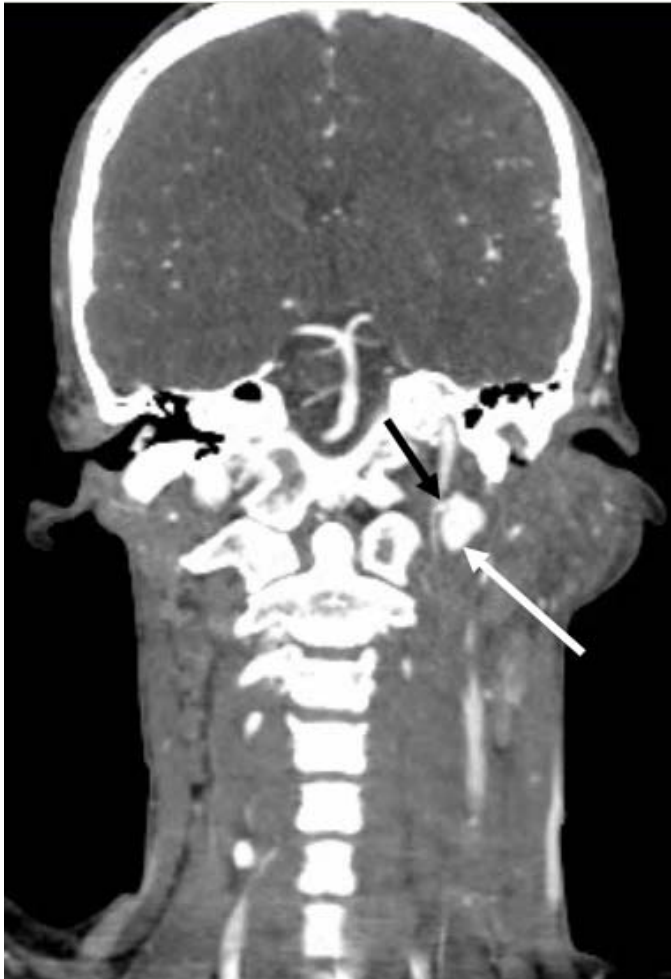


Fig. 2. Coronal reformatted image of CT Angiogram demonstrating Internal Carotid Pseudoaneurysm (white arrow) and neck (black arrow). Note the soft tissue swelling of left sub-auricular region of neck from bleeding.

Case Report

A 26 year old security guard presented to Balad Expeditionary Hospital with a gun shot wound to the face. The entrance wound was directly under the left eye and the exit wound was on the lower left neck. He was hemodynamically stable on arrival and had a GCS of 15. However, due to the significant left buccal swelling and mild tracheal deviation, he was intubated to protect his airway. A CT scan of the head and neck were ordered with thin axial slices and sagittal/coronal reformats obtained.

Summary of Imaging Findings

The head CT was negative but the facial CT scan showed a left maxillary fracture, significant left neck swelling with tracheal deviation and a left ICA pseudoaneurysm. A diagnostic CT angiogram was performed and 3D reformatted images were obtained. The ICA pseudoaneurysm was measured to be 2 cm in length and located just inferior to the skull base (Figures 1 and 2). A left vertebral artery pseudoaneurysm was also seen that measured 1.5 cm (Figure 1).

Description of Procedure

Access was obtained in the right common femoral artery. A 5F Davis catheter (Cook Inc, Bloomington, IN) was exchanged over a 035 Rosen wire for a 6F 90 cm Pinnacle Destination Guiding Sheath (Terumo Med Corp, Elkton, MD). The ICA pseudoaneurysm neck was sub-selected with a 150 cm Renegade 2.5F Microcatheter (Boston Scientific, Natick, MA) and a 018 182 cm Transcend EX Microwire. A 10mm X 20 cm Interlocking Detachable Coil and a second, 8mm X 20 cm Interlocking Detachable Coil (both Boston Scientific, Cork, Ireland) were deployed into the ICA pseudoaneurysm under fluoroscopic guidance (Figure 3A and Figure 4). The vertebral pseudoaneurysm was also viewed under angiography. Due to its smaller size, it was expected to resolve on its own and was not coiled.

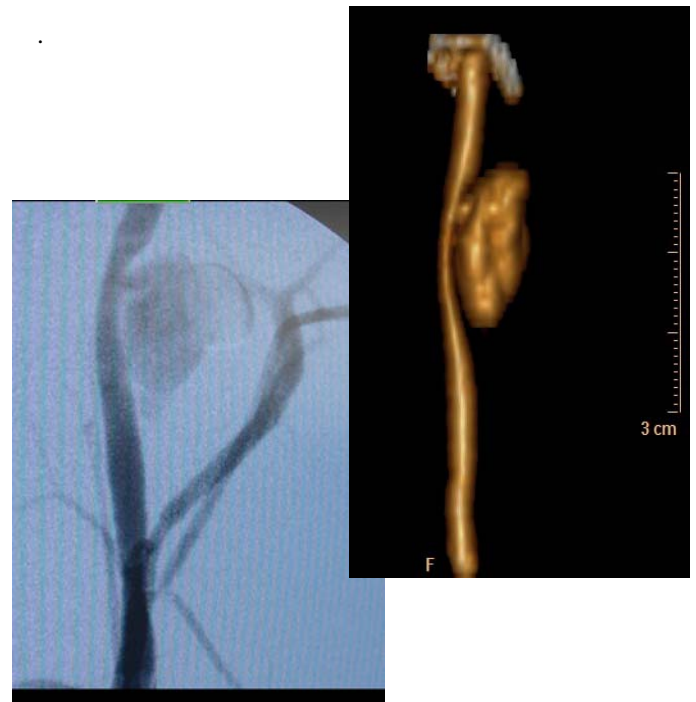

Fig. 3A. C-Arm interoperative selective ICA angiogram with isolated CTA 3-D correlation (3B).

Contrast was injected through the Guiding Sheath between the coils to confirm patency of the carotid artery. The detachable coils resulted in a significant decrease in the flow to the pseudoaneurysm. The Renegade Microcatheter was removed and a left cerebral angiogram was performed. The angiogram confirmed normal perfusion with no evidence of distal thrombus (Figure 5). The patient tolerated the procedure without any complications.

A follow-up helical CT scan was performed the following day. The left carotid 2 cm pseudoaneurysm was now 90% occluded. The patient was transferred later in the day to a hospital outside Baghdad and was doing well at that time of transfer.

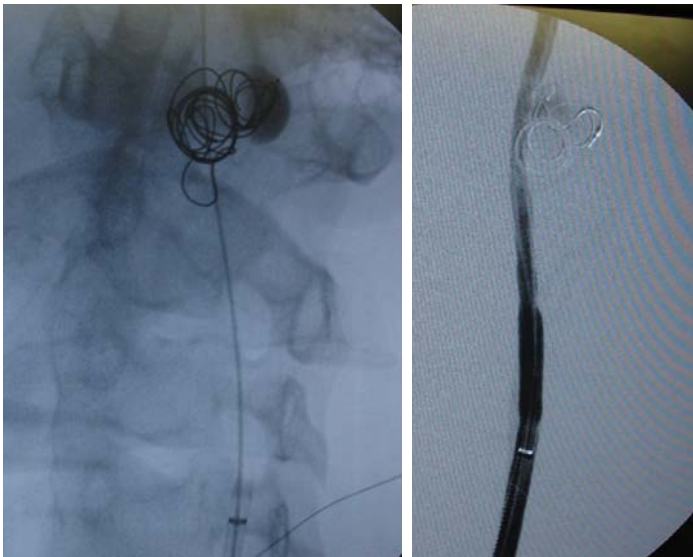


Fig. 4. Selective coiling of pseudoaneurysm.

Discussion

Several imaging modalities can be used to diagnose pseudoaneurysms. Femoral pseudoaneurysms are often diagnosed with ultrasound. Any expanding pulsatile mass with associated tenderness should be expeditiously viewed under ultrasound. Most pseudoaneurysms are simple single sacs but some can be multi-lobe complexes. Particular attention should be focused on the neck of the pseudoaneurysm as a long narrow neck is easier to compress compared to a wide neck. Other imaging modalities can include contrast-enhanced CT with reconstructions and MR scanning. In addition, angiographic imaging is the “gold standard” for definitive diagnosis of ICA pseudoaneurysms because ultrasound is usually not sensitive enough in the neck.³

Treatment options for pseudoaneurysms often depend on size and location. If they are small, femoral pseudoaneurysms may spontaneously clot without any further treatment. Compressing the femoral pseudoaneurysm neck with an ultrasound probe can also be effective. If less than 2cm in diameter, femoral pseudoaneurysms have a 70% chance of spontaneous thrombosis with compression therapy.⁴ Ultrasound-guided thrombin injection is another treatment option for femoral pseudoaneurysms. The injection of thrombin (0.2-0.5 mL of 1000 U/ml) is often very successful for instantaneous thrombosis.⁵ If the pseudoaneurysm is large, expanding, or painful then there is increased risk of rupture and should be repaired surgically. Surgical repair involves exposing the arterial defect or puncture and repairing with it with multiple sutures. If infection is present, proper debridement, and graft replacement is indicated.

Pseudoaneurysms in the head and neck offer a unique challenge due to the concern for neurological deficits. If a carotid pseudoaneurysm is small, it can be managed with anticoagulation and close follow-up. Since this case occurred in a deployed combat hospital, managing any follow-up care is extremely challenging. Thus, it was decided that this patient would require more definite management upfront.

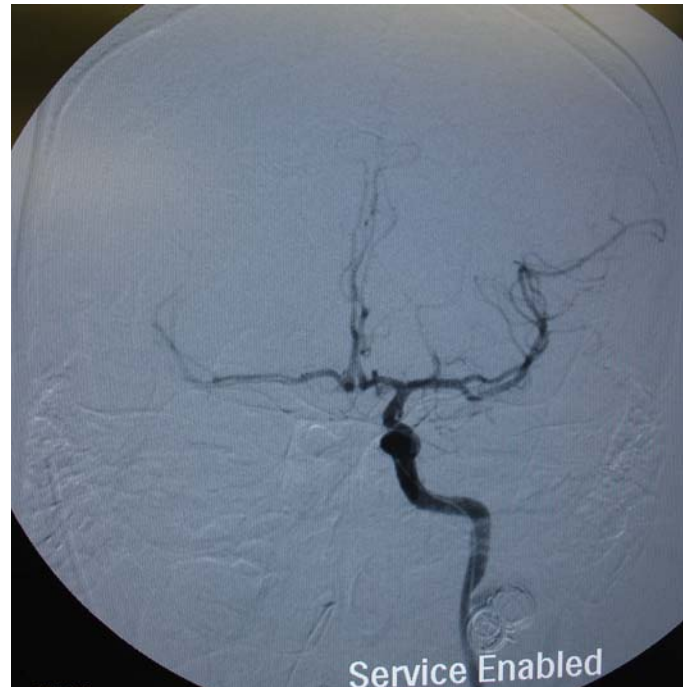


Fig. 5. Selective ICA showing adequate intracerebral patency. Note the coils inhibiting flow into pseudoaneurysm.

Several procedures have been described for the repair of internal carotid pseudoaneurysms. Depending on their location, they can be extremely difficult to treat via surgical means. Risks can include potential thrombosis, embolization, and rupture. Surgery often involves occlusion of the ICA proximal and distal to the defect with bypass grafting. Some of these surgical techniques sacrifice the carotid artery either by ligation or application of a clamp to the vessel. Surgical techniques often involve using balloon test occlusion (BTO) of the carotid artery which allow for accurate prediction of post-procedure neurological deficits after the artery has been occluded. The neurologic ischemic rate after a clinically tolerated BTO varies from 5% to 20% and the rate improves further if performed with a hypotensive challenge as reported by Standart et al.⁶

Endovascular techniques include the use of coils and stents and may allow access to the distal carotid not accessible via a surgical neck approach. Isolated pseudoaneurysm obliteration can be performed using metallic coils and/or detachable balloons. Lempert et al⁷ reported use of Guglielmi electrolytically detachable platinum coils (GDC's) in eleven cases--10 ICA pseudoaneurysms and 1 vertebral artery pseudoaneurysm. All eleven pseudoaneurysms were effectively treated with GDC embolization with only one complication of an occluded right frontal branch of the middle cerebral artery. This occlusion resolved with heparin and produced no clinical sequelae. In addition, Sclafani et al⁸ reports the use of coil occlusion specifically on ICA injuries from gun shot wounds. Seventeen patients underwent transcatheter arterial embolization of the ICA with bleeding controlled in all patients.

Endovascular stents have also been used for many years to repair ICA pseudoaneurysms. Bare stents are often used in conjunction with coiling. Bare stents can be placed across the

neck of a saccular aneurysm to promote aneurysm thrombosis while maintaining vessel patency. Covered stents can also be used to reinforce the vessel wall, thereby reducing the risk of rupture. Covered stents offer the advantage of not requiring further coiling. However, covered stents are associated with an increased risk of clot formation and require anticoagulation. In this case, stents were not available given the deployed hospital environment and thus only coiling was used for the repair.

Note: The views expressed in this article are those of the authors and do not necessarily reflect the official policy or position of the Air Force, the Department of the Defense, or the U.S. Government.

Category 1 CME or CNE can be obtained on the MedPix™ digital teaching file on similar cases by following the following link. Many Radiology Corner articles are also a MedPix™ Case of the Week where CME credits can be obtained.

<http://rad.usuhs.mil/amsus/>

References

- ¹Townsend CM, Beauchamp RD, Evers BM, Mattox KL. Aneurysmal Vascular Disease-Ch. 64 *Sabiston Textbook of Surgery: The Biological Basis of Modern Surgical Practice*. 17th Ed. Philadelphia, PA: Saunders; 2004.
- ² Knight CG, Healy DA, Thomas RL. Femoral Artery Pseudoaneurysms: Risk factors, Prevalence and Treatment Options. *Ann Vasc Surg* 2003; 17:503-508.
- ³ Townsend CM, Beauchamp RD, Evers BM, Mattox KL. Vascular Trauma-Ch.66 *Sabiston Textbook of Surgery: The Biological Basis of Modern Surgical Practice*. 17th Ed. Philadelphia: PA: Saunders. 2004.
- ⁴ Townsend CM, Beauchamp RD, Evers BM, Mattox KL. Aneurysmal Vascular Disease-Ch. 64 *Sabiston Textbook of Surgery: The Biological Basis of Modern Surgical Practice*. 17th Ed. Philadelphia, PA: Saunders; 2004.
- ⁵ Jackson JE, Allison DJ, Hemingway AP. Ch7. Principles, Techniques, and Complications of Angiography. In: Grainger RG, ed. *Grainger and Allison's Diagnostic Radiology: A Textbook of Medical Imaging*. 4th Ed. London, UK: Harcourt; 2001.
- ⁶ Standard SC, Arvind A, Gutermann LR, et al. Balloon Test Occlusion of the Internal Carotid Artery with Hypotensive Challenge. *AJNR Am J Neuroradiol* 1995; 16: 1453-1458.
- ⁷ Lempert TE, Halbach VV, Higashida RT, et al. Endovascular Treatment of Pseudoaneurysms with Electrolytically Detachable Coils. *AJNR Am J Neuroradiol* 1998; 19: 907-911.
- ⁸ Sclafani SJA, Scalea TM, Hoffer EK, Herskowitz MM, Pevsner P. Interventional Radiology in the Treatment of Internal Carotid Artery Gunshot Wounds. *JVIR J Vasc Interv Radiol* 1995; 6: 857-861.