

Radiology Corner

Gun Shot Wound to the Chest of a Military Working Dog

Guarantor: 2LT Meghan Galer, MSC, USA¹

Contributors: 2LT Meghan Galer, MSC, USA¹; Donna Magid, MD, MEd²; Les Folio, USAF, MC, SFS³

*Note: This is the full text version of the **Radiology Corner** question published in the May 2009 issue, with the abbreviated answer in the June 2009 issue.*

This Military Working Dog (MWD) was shot in the chest during combat operations in Iraq. Military Working Dogs are critical to the safety and well-being of deployed troops in combat operations and, as such, they are triaged and treated in our combat hospitals just like any other soldier; their speciation is not a factor in their triage status. This case familiarizes military physicians with the basic canine anatomy, positioning, and radiological technique they should be aware of before deploying. We also strive to raise awareness of the vital roles that these MWDs play for our forces, counter any concerns that may arise over the issue of treating these dogs in human facilities, and leave the reader feeling better prepared to handle the situation should they ever find themselves poised to save one of our four-legged warriors.

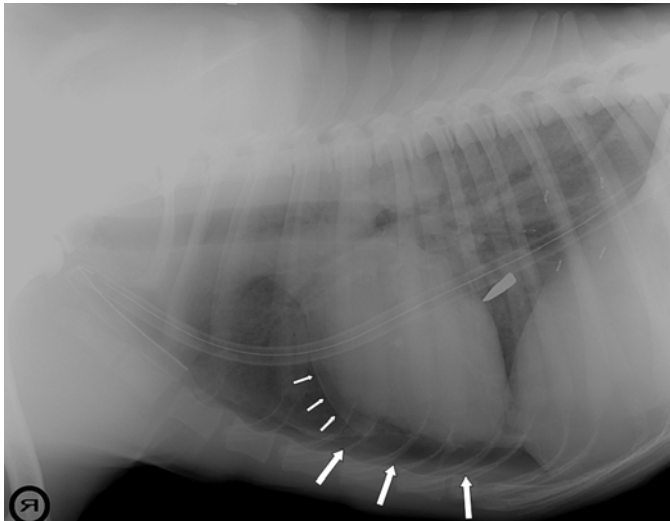


Fig. 1: Right lateral thoracic projection shows the bullet in the lower lung fields pointing in the direction of the entrance (not uncommon). Note the chest tube and pneumopericardium (small arrows) and increased cardiac-sternal space (larger arrows). This is how veterinary radiologists view lateral projections. For orientation purposes, superior is to the left and inferior to the right, anterior is down and the spinous processes are at the top. Note the transition of spinous processes angle inferiorly until the lower thoracic spines that point superiorly (termed the anticlinal vertebrae).

¹ School of Medicine; Uniformed Services University of the Health Sciences, Bethesda, Maryland 20814-4799

² Department of Radiology and Radiological Science, Johns Hopkins University Medical Center, Baltimore, MD, 21287

³ Department of Radiology and Radiological Sciences; Uniformed Services University of the Health Sciences, Bethesda, Maryland 20814-4799

Reprint & Copyright © by Association of Military Surgeons of U.S., 2006.

Introduction

This dog, a Belgian Malinois, was shot in the chest. He arrived at the Air Force Theater Hospital with minimal bleeding and an apparent hemopneumothorax, but was hemodynamically stable. The isolated AK-47 round was identified and a chest tube was placed without gross evidence of remaining pneumothorax on chest radiograph. The dog was evacuated with his trainer stateside for definitive treatment, as per routine for any military deployed asset.

Summary of Findings

Ventrodorsal (VD; similar to human AP) and lateral views of the chest were obtained (Fig. 1, Fig. 2). Note the intact bullet on the right side and the chest tube on the left. This transmediastinal penetration resulted in a pneumopericardium, sparing the great vessels. There is a small amount of air in the anterior (cranial) ventral thorax and atelectasis of the right caudal lung lobe. There is increased separation between the heart and the sternum (larger arrows in Figure 1) owing to the atelectasis of the dependent right caudal lung lobe. Rightward mediastinal shift is seen in the VD view, and surgical staples are visible in the left lateral chest wall.

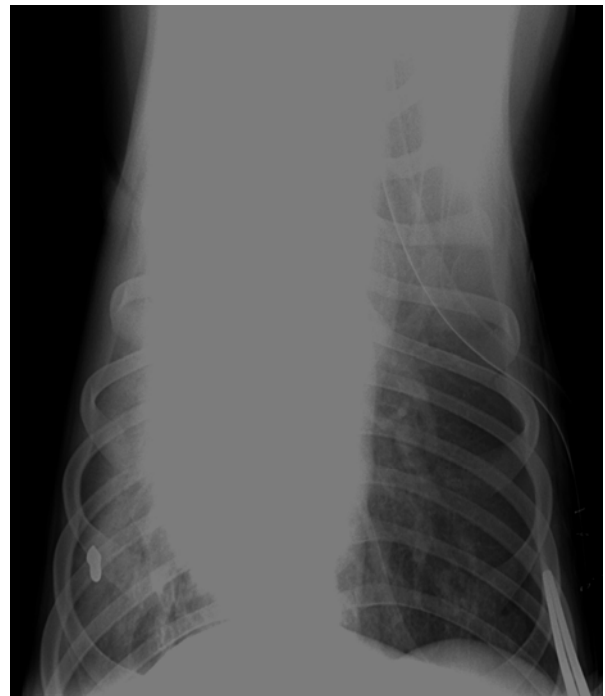

Fig. 2: Ventrodorsal (VD or AP) chest radiograph of dog showing metallic bullet in the right caudal lung lobe. The mediastinum is normal in configuration for canine radiographic anatomy, though it is shifted slightly to the right. Also note the increased opacity in the right lower lung field secondary to atelectasis (and minimal rotation).

Diagnosis

GSW to chest with pneumopericardium.

Discussion

Military Working Dogs play a vital and often unheralded role in our national defense. The Department of Defense (DoD) spends significant time and money on the training of these animals to perform tasks for which they are simply biologically better equipped for than any human or machine, such as sentry duty and explosives detection. These dogs are out there on the front lines, obediently performing the tasks for which they've been trained, and saving soldiers' lives with every explosive they detect and early warning sign they give. For that reason, they are force multipliers. It is therefore in the interest of the mission that prompt medical care in the event of traumatic injury be as much of a priority for these MWDs as it would be for any other downed soldier (Fig. 3). And if the veterinarian isn't around, the task may fall to you, Doc.

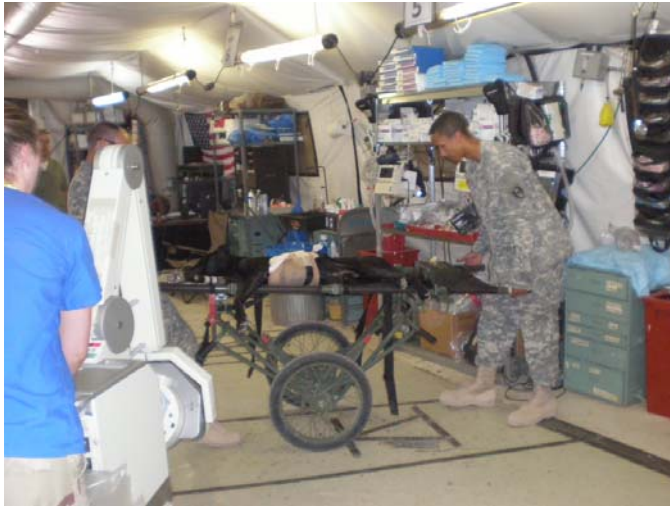

Fig. 3a: Our patient in the Emergency Department at Balad, Iraq on a NATO litter, intubated, anesthetized and stabilized with IV fluids.

History of military working dogs: Pack dogs were in use by the military as far back as the Revolutionary War. World War II saw expansion of war dog training divided into eight areas as follows: sentry dogs, attack dogs, silent scout dogs, messenger dogs, casualty dogs, pack dogs, sledge dogs (trained to find downed airmen in snowy areas that would be otherwise inaccessible to rescue crews), and tactical dogs.¹ Over 10,000 of these dogs were trained throughout the war at one of five War Dog Reception and Training Centers, the first one having been established at Front Royal, VA, in 1942.² Many of these dogs were deployed to the European or Pacific theaters. There, most of them worked as scout dogs, detecting an enemy presence up to 1000 yards further away than any man would have been able. In the Korean War, the Army employed about 1,500 dogs; in the Vietnam War, about 4,000. One of the most famous war dogs, a German Shepherd called "Nemo" is credited with having saved the life of his handler

and preventing "further destruction of life and property" by detecting and attacking a force of Viet Cong commandos who had infiltrated his post at the Tan Son Nhut Air Base on December 4th, 1966. Military Working Dogs were also deployed in Operations Desert Storm and Desert Shield, and most recently in Operations Enduring Freedom and Iraqi Freedom.³

Military Working Dog program: The United States Air Force is the single manager for the MWD program in the DoD, and the United States Army Veterinary Corps is the executive agent for veterinary services. The German Shepherd and the Belgian Malinois are the predominant breeds employed, though other breeds are also used. Each dog's handler is responsible for the daily care and grooming of the MWD, as well as the dog's skills and physical training, so the dog and trainer are generally considered as a unit. Importantly, dogs are considered property of the military, and as such, are authorized diagnostic procedures, treatment and medical evacuation without differentiation from their biped counterparts.⁴

Training, types of military working Dogs: Currently, MWDs and their handlers train as part of the 341st Training Squadron, at Lackland Air Force Base, Texas, in conjunction with dogs being trained for use by other Federal Agencies such as the Transportation Security Agency and the U.S. Border Patrol. The DoD currently maintains four categories of dogs as follows: Patrol/Explosives dogs, Patrol/Narcotics dogs, Patrol only dogs, and Detector only dogs. Individual dogs are trained to detect either drugs or explosives, never both. The demand for Patrol/Explosives dogs is increasing. They are the most highly trained category of dog and comprise more than fifty percent of the MWDs trained per year. Currently, an undisclosed number of MWDs are at work in Iraq and Afghanistan.

At present, there is neither policy nor official guidance regarding the use of human medical facilities for MWDs in emergent situations. Current practice seems to rely on grassroots attempts by veterinary officers to develop working relationships with commanding officers of Military Treatment Facilities (MTFs) or Medical Centers in case one requires assistance from the other.

Hypothetical infection concerns: An understandable concern on the part of physicians is that of the cleanliness of the animals and the risks of zoonotic infection that they may pose. A review of the literature however, though mostly based on studies of animal visitation programs in civilian hospitals, implies that these concerns are likely unfounded. In 1992, Huntington Memorial Hospital in Pasadena, California, reported that in five years of their Animal Assisted Therapy program, in which they hosted 3,281 dog visits to 1,690 patients, not a single zoonotic infection was reported.⁵ A second study of a similar program over two years at Children's Hospital Medical Center of Akron, Ohio, reported no increase in the rate of infection during that period.⁶

Obviously there are different exposure and risk factors to be considered in a battlefield encounter with an injured animal, and all the usual personal protective measures, including body substance isolation procedures and avoidance of contact with non-intact tissues, should be observed. It should go without saying that special care ought to be taken when either human or dog is on isolation precautions. Also, animals without airway compromise should be muzzled, as the stress of being injured may lead them to behave unpredictably. When these conditions are met, the risk of vertical contagion from canine to human is, in fact, minuscule, and far less than the known risks of human-to-human contagion under similar conditions. There are a few tropical diseases for which extra precautions must be taken, however these are found only in well-defined geographic theaters. Regarding these, the risk of vertical contagion still remains low because MWDs, which are constantly supervised and share living space with human military personnel, actually have very little exposure to local disease reservoirs. Lastly, unlike humans, canine patients present no risk of HIV or hepatitis C transmission.

Emergency management of Military Working Dogs:

So, what would you want to know in the event that the next patient to roll through the door of your MTF is an MWD? Relax. Your first priority is to calm and immobilize the dog. Then, just start with your ABCs.

A-Airway

Dogs are routinely intubated using human endotracheal tubes. A large dog such as a German Shepherd will usually require a size 9/10 tube, while a smaller dog such as a Brittany Spaniel will usually require a size 6/7. It's easiest to intubate dog from a right-side-up face-to-face angle and pull *down* on the upside-down laryngoscope while someone else holds the dog's snout steady. A stylet is not usually needed. Dogs will often breath on their own once intubated, and ongoing manual ventilation is often not necessary.

B-Breathing

There are only two respiration rates to remember if you find yourself pinch-hitting for the veterinarian: breathing, or not breathing. If the dog is not breathing, ventilate at a rate of 10-12 breaths per minute.

C-Circulation

Heart rates vary with the size of the dog, with smaller dogs having generally higher heart rates (just like smaller children). In a Beagle, a heart rate of up to 200 beats per minute (bpm) may be normal, but in a German Shepherd one as low as 60 bpm may also be normal.

Systolic blood pressures on dogs can best be obtained by palpation using a pediatric cuff positioned *below* the 'elbow' of either the front or hind legs, as pedal pulses can

be detected manually or with the use of Doppler in either location. Anything below 80-90 mmHg is cause for concern, and fluid (either NS or LR) should be administered to bring the blood pressure up to about 100 mmHg.

The tongue and gums of a dog can offer hints regarding perfusion status. If the dog is adequately perfusing, this tissue should be, like a human's, pink. If it's very pale, suspect bleeding. If it's blue, suspect inadequate ventilation. Pulse oximetry can be obtained using human equipment on the dog's tongue, toes, or shaved ear.

The normal temperature for dogs regardless of breed is about 99.5-102.5° F.

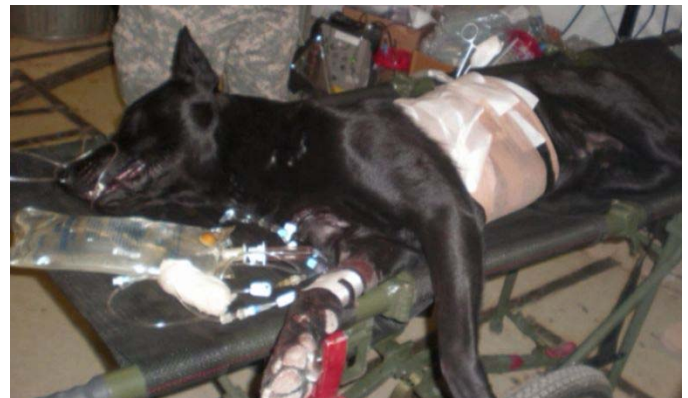


Fig. 3b: A close up view of our Belgian Malinois while in the ED. He is intubated (without need for ventilator), has an IV in his right front leg, and the chest tube and bandaging are visible around his chest.

Emergency Procedures

Emergency tracheotomies are done more distally, between the 3rd and 4th or the 4th and 5th cartilage rings. Chest tubes are placed in the 9th intercostal space in the dorsal third of the thorax. Dogs have thirteen ribs instead of twelve; it generally is easier to count up from caudal to cranial to find the 9th intercostal space. A dog's mediastinum is fenestrated, so a chest tube placed on one side should help an injury on either side. For the same reason, dropping an ipsilateral lung can unexpectedly drop the contralateral lung as well.

The easiest place to start a peripheral line on a dog is in the cephalic veins on the anterior aspect of their front legs or the saphenous veins on their lateral ankles. The best places for central line placement are the external jugular vein (the internal jugular vein, more commonly used in humans, is less accessible in a dog) or the femoral vein, which, as in the human, can be found medial to the palpable femoral artery. If you're really up a creek and need to give blood to a dog, you can draw fresh blood from any other dog and administer it via heparinized filter tubing immediately into the sick dog. Dogs do not require typing and crossmatching for their first transfusion, even between breeds.

Labs

The normal ranges for an arterial blood gas for a dog are the same as for a human. Chemistries are also analogous. A normal WBC count for a dog is about 8,000-16,000, and a normal Hematocrit falls into the range of 35-45%, with less than 20% being cause for alarm.

Radiology

Recommendations for radiological imaging of MWDs are published in *The Handbook of Veterinary Care and Management of the Military Working Dog*.⁷ Some important procedural differences to keep in mind are that chest and abdominal images for dogs are ventrodorsal and lateral (right lateral thoracic view) instead of anterior/posterior and lateral (Figure 4). Positioning the dog for the VD image will require help; dogs cannot abduct their limbs, but someone can extend and hold the limbs away from the trunk, minimizing their supposition on the image. Either side may be used for the lateral views if the area of interest is the thorax, and if need be, a dorsoventral view may suffice instead of a ventrodorsal view. If you're also looking at the abdomen, the right lateral view is preferred for visualization of the stomach and liver. When possible, both laterals are ideally obtained.

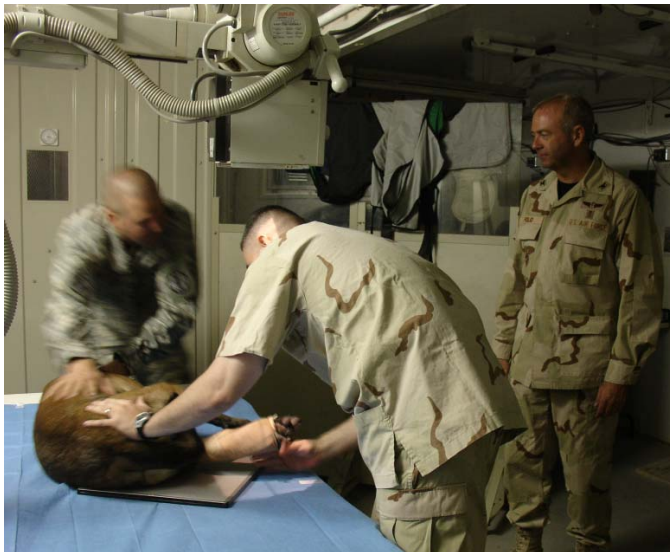

Fig. 4: Positioning of another MWD in an isoshelter (deployed plain radiography unit). This dog was getting a radiograph of the hind extremity.

There are some anatomical differences to keep in mind when reviewing canine films. As mentioned previously, dogs have thirteen ribs. They also have one extra thoracic vertebrae, and two extra lumbar vertebrae. At about T11, their spinous processes start to angle cranially (termed the anticlinal vertebrae, see fig. 1). The lung lobulation of a dog also differs significantly from that of a human. On their left, dogs have two lung lobes: cranial and caudal. On their right, they have four lobes consisting of cranial, middle, and caudal lobes, as well as a variable accessory lobe.

Pharmacology

Dogs should not receive human acetaminophen or most non-steroidal anti-inflammatory drugs. Dogs metabolize these differently and they tend to cause ulceration of their gastrointestinal systems. Aspirin also has an exaggerated effect in dogs. Ibuprofen is okay as an antipyretic, though only about a third of the human dose is required for a dog of comparable weight. Opioids are fine for pain. Most human antibiotics are also okay but are usually required in higher doses.

More detailed information on emergency and radiological procedures for MWDs is available in *The Handbook for Veterinary Care and Management of the Military Working Dog*.

In the process of assembling this case report, the authors recognized that MTF personnel might benefit from a single depot of references and guidelines for the emergency treatment of MWDs, that they can access quickly when the need arises. To that end, the authors have initiated a website that may be further developed into a single, easily accessible, and understandable resource portal, developed for providers in MTFs who find themselves involved in the emergency treatment of an MWD.⁸ We envision this to include general guidelines, medication doses, and instructions for emergency and radiological procedures, all presented with reference to the knowledge of humans that the physician already has, as well as emergency contact information for veterinary specialists and guidelines for medical evacuation to a veterinary facility.

In summary, Military Working Dogs have been vital members of the U.S. Military nearly since its inception. They perform roles that no human soldier ever could, saving American lives and boosting troop morale in the process. Like any of our soldiers, they deserve top-notch medical care, and sometimes that care needs to be provided in human facilities, by physicians without veterinary training. In such instances, the risks of zoonotic infection are largely unsubstantiated and unlikely. If you find yourself in a situation where you need to provide emergency medical treatment, just relax and do the best you can; mammals are mammals. Our case highlights how medical personnel can employ basic diagnostic and resuscitative techniques to help save a soldier's best friend, so that he can, in turn, save more soldiers.

Acknowledgements: *The authors would like to thank David Fletcher, DVM, the Department of Defense Military Working Dog Veterinary Services radiologist, for his imaging expertise and guidance in this report. We would also like to thank Emily Rogell, DVM, of the Metropolitan Emergency Animal Clinic, Rockville, MD, for her guidance in emergency veterinary procedures. In addition we thank Milita Rios-Samaniego of the Lackland Air Force Base Security Forces Museum, for her preliminary information and guidance, and Krystle Avery, a James Madison University student, for her assistance in initial literature review.*

Category 1 CME or CNE can be obtained on the MedPix™ digital teaching file on similar cases by opening the following link. Many Radiology Corner articles are also a MedPix™ Case of the Week where CME credits can be obtained.

<http://rad.usuhs.mil/amsus.html>

References

- ¹ English TL: The Quiet Americans: A History of Military Working Dogs, Lackland AFB, AETC, 2000.
- ² Born KM: The Military Working Dog: History. The MilitaryWorking Dog Foundation, Inc. 2006.
<http://www.militaryworkingdog.com/history/>
- ³ Department of the Army. FM 3-19.17. Military Working Dogs. 2005.
- ⁴ Toffoli C, Rolfe D: Challenges to Military Working Dog Management and Care in the Kuwait Theater of Operation, Mil Med 2006 (October); 171(10):1002-1005.
- ⁵ Jorgenson J: Therapeutic Use of Companion Animals in Health Care, Journal of Nursing Scholarsh 1997; 29(3):249-254.
- ⁶ Lerner-DurJava L: Pet Visitation is an Infection Control Issue? Am J Infect Control 1994; 22:112.
- ⁷ Rolfe DS: The Handbook for Veterinary Care and Management of the Military Working Dog, March, 2004.
- ⁸ Folio L, Galer M. Imaging the Military Working Dog. Radiologist Deployment Preparation Website:
http://rad.usuhs.edu/project44R3/dogs_page.html Accessed December 2008.