

## Radiology Corner

### Colonic Adenocarcinoma detected by Virtual Colonoscopy Screening

**Guarantor:** ENS Brendon G. Tillman, USN, MC<sup>1</sup>

**Contributors:** ENS Brendon G. Tillman, USN, MC<sup>1</sup>; COL Les R. Folio, USAF, MC, SFS<sup>1</sup>; J. Richard Choi, ScD, MD<sup>1</sup>

*Note: This is the full text version of the radiology corner question published in the November 2006 issue, with the abbreviated answer in the December 2006 issue.*

This case report is designed to familiarize military physicians with virtual colonoscopy. Screening for colorectal cancer is significant because it is the third most diagnosed (1) malignant neoplasm and second leading cause of cancer related mortality in the United States. (2) Despite being so deadly, colorectal carcinoma is also one of the most preventable types of cancers. Virtual colonoscopy is an excellent alternative to optical colonoscopy for colon cancer screening. It is minimally invasive, less time consuming and possibly more comfortable for the patient. The authors believe that virtual colonoscopy will have a large positive impact on public health because of increased compliance and earlier detection of colon cancer should substantially reduce the total amount of deaths from colon cancer.

#### Introduction

Virtual colonoscopy (VC) is a quick method used to screen for presence of colon polyps. Optical colonoscopy (OC) can confirm the presence of the polyp(s) and allows for tissue biopsy and polypectomy. The following case is an example of adenocarcinoma discovered on screening VC.

#### History

A 51-year-old male with no known symptoms presents for routine screening for colorectal carcinoma.

#### Summary of Imaging Findings

Virtual colonoscopy can create a three dimensional (3D) anatomic model of the colon using data from volumetrically acquired computed tomography (CT) images (Fig 1A). An axial slice from the CT scan shows a 0.9 cm pedunculated polyp in the sigmoid colon, approximately 60 cm from the anus (Fig. 2A). A 3D endoluminal view of the colon shows a better depiction of the polyp (Fig. 1B, 2A, 3, 4A).

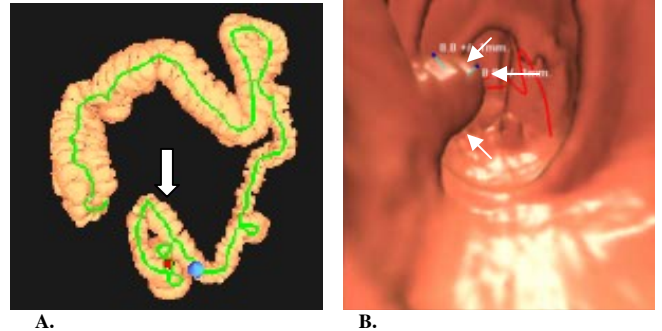


Fig. 1A, B. Computer generated 3D model of the colon (A) and endoluminal view of the colon with polyp (arrows, B).

The patient was recommended to undergo OC to confirm the presence of the polyp. The OC confirmed the presence of a 1.5 cm pedunculated polyp, grossly measured with a stalk, located 50 cm from the anus (Fig. 4B). The polyp was biopsied and sent for pathologic diagnosis. Biopsy of the polyp showed micro-invasive colonic adenocarcinoma, without invasion of the lymphatic, vascular, or perineural space.

#### Patient Discussion

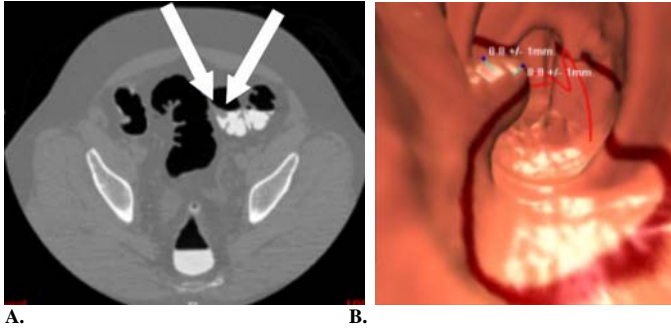
Differential considerations for a polypoid mass on VC include: hyperplastic polyp, fibroblastic polyp, inflammatory polyp, lymphoid polyp, adenoma (tubular, villous, and tubulovillous), intramucosal colonic adenocarcinoma, and invasive colonic adenocarcinoma. Retained fecal debris is often considered, however, ruled out in this case using workstation tools (hounsfield unit interrogation, supine vs. prone views, etc.) and having characteristic findings of a polyp. A hyperplastic polyp is a benign growth of the colonic endothelium. Adenomas are neoplastic benign growths of the colonic epithelium that are direct precursors to adenocarcinoma. Tubular adenomas arise from tubular glands of the colon wall and account for a majority of adenomas found in the colon. Villous adenomas develop from the villous projections and only make up 1% of adenomas found within the colon. Tubulovillous adenomas are a combination of tubular and villous adenomas and account for 5% to 10% of adenomas discovered. Intramucosal carcinomas are malignant cells confined to the bowel mucosa. Invasive carcinomas occur when these malignant cells extend into the submucosa of the colon wall. (3)

Treatment for colorectal carcinoma depends on the staging of the disease. Treatment options include partial or total

<sup>1</sup> Department of Radiology and Radiological Sciences; Uniformed Services University of the Health Sciences, Bethesda, Maryland 20814-4799

Reprint & Copyright © by Association of Military Surgeons of U.S., 2006.

colectomy, radiation therapy, and chemotherapy. Radiation therapy may be used before surgery to shrink the tumor or after surgery as an adjuvant therapy. If the cancerous polyp is small, laparoscopic surgery is often utilized due to the decreased amount of side-effects and healing time as compared to open surgery. Once the cancer is staged, the decision to use chemotherapy is determined by presence of local or distal metastasis. (4)



**Fig. 2A, B.** The 2 dimensional axial image of the CT scan (A) corresponding to the red line in image (B) can help confirm the presence of a polyp. The polyp is confirmed as soft tissue density on the CT scan (arrows).

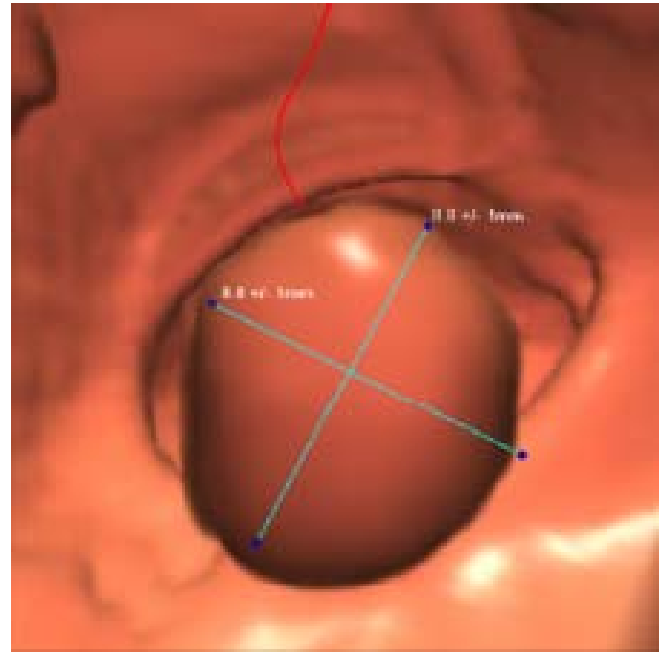
### Discussion

Colorectal carcinoma is one of the most preventable types of cancer. It is recommended that all men and women over the age of 50 get colon cancer screening every 5 to 10 years. (5) Those at high risk are sometimes screened earlier. However, it is noted that only approximately 30% of people eligible to get screened actually get screened. (6) This statistic is important because the latency period for colorectal carcinoma is 10 to 20 years. The traditional gold standard for colorectal screening has been OC, which is invasive, requires sedation, and a full bowel cleanse the day before. This may be too overwhelming for asymptomatic individuals that should be screened. One hope is that VC will help make the screening process more convenient (hence increased compliance) and less invasive without jeopardizing the sensitivity and specificity of the test.

Computed tomography colonography or VC is a technique that utilizes volumetrically acquired helical CT scan of the abdomen to produce two-dimensional and three dimensional images of the colon. (6) These images can detect colon polyps of varying sizes. To get the best image of the colon, carbon dioxide is used to inflate the colon through a flexible rectal tube (about the size of a pencil).

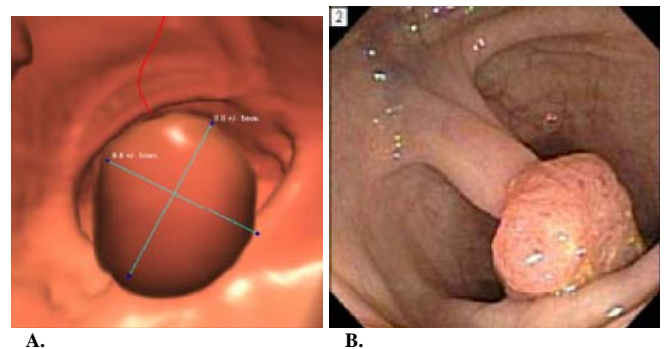
Phosphosoda preparations are often used before a VC exam as a bowel cleansing regiment. However, phosphosoda preparation carries an increased risk for patients with severe systemic disease or electrolyte imbalance. (8) In those patients, polyethylene glycol solution known as Colyte can be used for bowel cleansing. (9) Oral contrast with stool tagging is used in patients at some centers to increase sensitivity and specificity of the VC. Research is underway to see if VC can be performed without the use of a pre-procedure colon cleansing.

Virtual Colonoscopy is currently being used for colorectal screening at select military medical centers for active-duty and other military beneficiaries. (10) VC is also used after failed optical colonoscopy to examine the unexplored bowel.



**Fig 3.** Close up of the view of the polyp in our case in the endoluminal view.

It is hoped that less invasive and more convenient means of colorectal screening will increase compliance. (10) Several studies have shown that VC is 83 – 100% sensitive and 93 – 100% specific for detecting polyps 1.0 cm and greater. (6) It is also accurate in detecting polyps sized between 0.6 – 0.9 cm. A large scale multi-center study by Dr. Pickhardt and Dr. Choi (10) found that VC was comparable to OC in detecting significant polyps 6mm and greater. However, other studies performed using older 2D forms of VC showed better sensitivity and specificity with OC. (11)



**Fig. 4A, B.** Virtual colonoscopy image (A) correlated with optical colonoscopy view (B) on the right where the stalk can be clearly seen.

Virtual colonoscopy also offers the benefit of scanning the entire abdomen. When someone undergoes a routine VC screening, the CT scan can be examined for significant extra-colonic abnormality. This added benefit only enhances the

importance of VC as a screening tool. However, it is important not to overcall incidental findings such as benign cysts, to avoid unnecessary additional studies.

Virtual colonoscopy is not without its negative side effects. The radiation exposure received is the main concern when using VC as a screening device. The amount of radiation exposure varies depending on equipment and scan protocol used. The slice thickness and radiation dose from the CT can be adjusted to limit the exposure of radiation to the patient, but may compromise image quality.

In conclusion, VC is a minimally invasive alternative for colorectal screening that has the potential to greatly increase compliance. The procedure is currently not covered under most health insurance policies. Currently, the procedure outside the military costs anywhere from \$500 to \$1500. However, the procedure is free for all active-duty military personnel, military retirees, and dependents within the Army, Navy, and Air Force at select military medical centers. There is a national study in progress being conducted by the American College of Radiology Imaging Network (ACRIN) (12) to confirm the positive findings from the earlier Department of Defense (DoD) study. The authors believe that VC will have a large positive impact on public health because early detection of colon cancer should substantially reduce the mortality from colon cancer.

*The opinions or assertions contained herein are the private views of the authors and not to be construed as official or reflecting the views of the Uniformed Services University of the Health Sciences or the Department of Defense.*

*Note: Follow this link for Category 1 CME or CNE in the case of the week in the MedPix™ digital teaching file. Example videos of VC can be seen on the MedPix™ posting.*

<http://rad.usuhs.mil/amsus.html>

## References

1. How Many People Get Colorectal Cancer? American Cancer Society® (n.d.). Retrieved July 22, 2006 from: [http://www.cancer.org/docroot/CRI/content/CRI\\_2\\_2\\_1X\\_How\\_Many\\_People\\_Get\\_Colorectal\\_Cancer.asp?sitearea=](http://www.cancer.org/docroot/CRI/content/CRI_2_2_1X_How_Many_People_Get_Colorectal_Cancer.asp?sitearea=)
2. Colon Cancer Awareness. Virtual Colonoscopy Screening Resource Center (n.d.). Retrieved July 22, 2006 from: <http://www.vcscreen.com/index2.php?id=3>.
3. Kumar V, Cotran R, Robbins S. Robbins Basic Pathology 7<sup>th</sup> edition. Saunders, Philadelphia, PA 2003.
4. Stancu M. Colonic Adenocarcinoma: Treatment Options. Retrieved August 15, 2006 from [http://www.gi-pathology.net/php/resource\\_main\\_xcellpath.php?name=colonic+adenocarcinoma](http://www.gi-pathology.net/php/resource_main_xcellpath.php?name=colonic+adenocarcinoma).
5. VC Screening. Virtual Colonoscopy Screening Resource Center (n.d.). Retrieved July 22, 2006 from <http://www.vcscreen.com/index2.php?id=2>.
6. Yee, J. (2004 November 17). Virtual Colonoscopy Prepares to Enter the Mainstream. Retrieved July 22, 2006 from University of California, San Francisco Web site: [http://www.radiology.ucsf.edu/research/01virtual\\_colonoscopy.shtml](http://www.radiology.ucsf.edu/research/01virtual_colonoscopy.shtml).
7. Versweyveld, L. (2002 March 11). PROTOCO2L colon insufflations system and Innerview GI workstation for virtual colonoscopy. Retrieved July 22, 2006 from <http://www.hoise.com/vmw/02/articles/vmw/LV-VM-04-02-6.html>.
8. Food and Drug Administration Science Background: Safety of Sodium Phosphates Oral Solution. (n.d.). Retrieved July 22, 2006 from: <http://www.fda.gov/cder/drug/safety/sodiumphosphate.htm>.
9. O'Connor SD, Summers RM, Choi JR, Pickhardt PJ. Oral contrast adherence to polyps on CT colonography. Journal Computer Assisted Tomography, 2006 Jan-Feb, 30, 1, 51-7.
10. Pickhardt PJ, Choi JR, Hwang I, Butler JA, Puckett ML, Hildebrandt HA, Wong RK, Nugent PA, Mysliwiec PA, Schindler WR. Computed Tomographic Virtual Colonoscopy to Screen for Colonic Neoplasia in Asymptomatic Adults. The New England Journal of Medicine, 2003 Dec 4, 349, 23, 2191-200.
11. Cotton PB, Durkalski VL, Pineau BC, Palesch YY, Mauldin PD, Hoffman B, Vining DJ, Small WC, Affronti J, Rex D, Kopecky KK, Ackerman S, Burdick JS, Brewington C, Turner MA, Zfass A, Wright AR, Iyer RB, Lynch P, Sivak MV, Butler H. Computed tomographic colonography (virtual colonoscopy): a multicenter comparison with standard colonoscopy for detection of colorectal neoplasia. JAMA, 2004 Apr 14, 291, 14, 1713-9.
12. ACRIN National CT Colonography Trial. (n.d.). Retrieved July 22, 2006 from <http://www.riainvision.com/invision/patientinfo/resources/patinfores/acrin6664.asp>.