

Radiology Corner

IED Fragment Embolism to Left Posterior Cerebral Artery

Guarantor: CAPT Vincent M. Timpone, USAF, MC*

Contributors: CAPT Vincent M. Timpone, USAF, MC*; MAJ Robert A. Jesinger, USAF, MC†; MAJ Todd Johnson, USAF, MC*; COL Peter Palka, USAF, MC, SFS*

Note: This is the full text version of the radiology corner question published in the September 2009 issue, with the abbreviated answer in the October 2009 issue.

We present a case of an IED fragment embolism to the left posterior cerebral artery in the combat setting. Missile fragment embolization is a rarely reported finding, and to our knowledge, this case is only the fourth reported example of missile embolism to the posterior cerebrovascular circulation. In this expanded online edition, we present a spectrum of embolized metallic foreign bodies.

Summary of Imaging Findings

A 20-year-old active duty male presented to the base emergency room following an improvised explosion device (IED) attack. On physical exam the patient had a Glasgow Coma Score (GCS) of 12 with signs of penetrating injury to his neck.

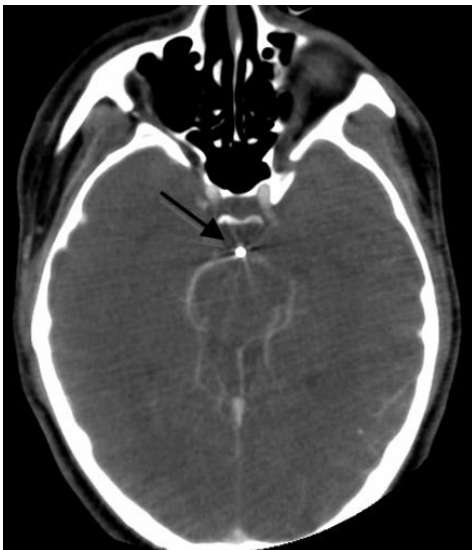

Fig. 1: Contrast enhanced CT angiogram of the head demonstrating a radiopaque foreign body (arrow) in the expected location of the basilar artery with enhancement of the posterior cerebral arteries.

A computed tomography (CT) angiogram of the cranio-cervical vessels (fig. 1) demonstrated a metallic foreign body in the basilar artery. The next day, the patient's neurological status deteriorated and a non-contrast head CT (fig. 2) demonstrated migration of the foreign body to the left posterior cerebral artery (PCA) territory.

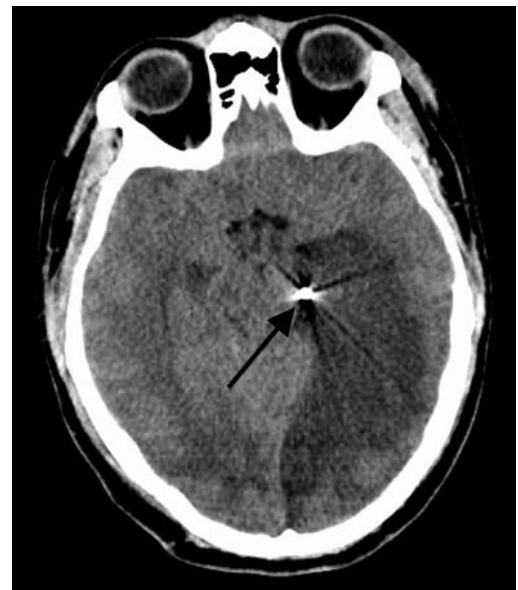

Fig. 2: Non-contrast CT of the head shows interval displacement of a radiopaque foreign body to the left PCA (arrow) with loss of gray white matter differentiation consistent with left PCA territorial infarction.

Discussion

Vascular embolism of bullet (missile) fragments is a rare occurrence with fewer than 200 cases reported in the literature since 1900.¹ In one of the largest series reported, Rich *et al* of the Vietnam vascular registry revealed an overall missile embolization incidence of 0.3% amongst 7500 casualties with known vascular trauma.² Migration of missile fragments to the cerebral circulation is an even rarer occurrence, with the majority involving the anterior circulation.³⁻⁵ To our knowledge, this is only the fourth reported case in the medical literature of a missile fragment embolism to the posterior cerebrovascular circulation.⁶

The occurrence of embolism after penetrating vascular trauma depends on missile size and velocity. Small size and low velocity are requirements for embolization to occur.⁷ To allow for intravascular embolization, the majority of the missile's energy dissipates in the soft tissues during

*Departments of Radiology (60 MDOS); David Grant USAF Medical Center, Travis AFB, CA 94535.

† Department of Radiology and Radiological Sciences; Uniformed Services University of the Health Sciences, Bethesda, Maryland 20814-4799

Reprint & Copyright © by Association of Military Surgeons of U.S., 2009.

penetration into the body; however, enough kinetic energy must remain for vessel entry.⁶

Missile fragment embolization usually occurs rapidly after entrance of the missile fragments into the vascular circulation, but may also occur up to days, weeks or in one reported case 1.2 years after initial injury.⁸ Embolizations are characterized as either venous (fig 3) or arterial (figs 1,2), with a few reported cases of paradoxical embolus via a patent foramen ovale (fig 4).^{9,10}

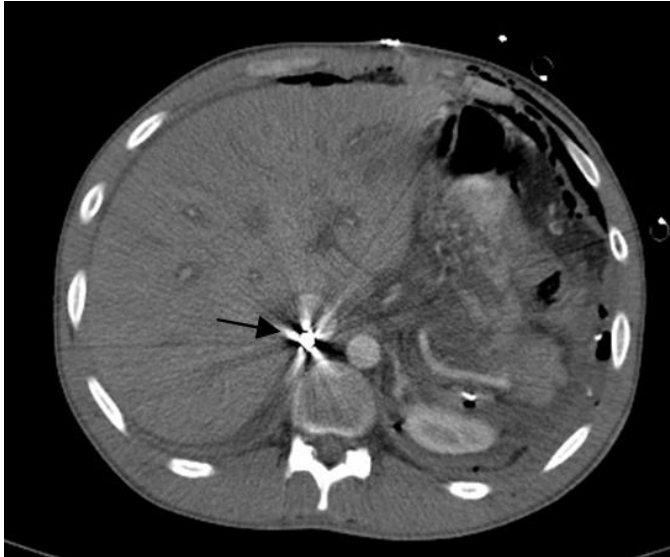

Fig. 3: Contrast enhanced abdominal CT scan showing a bullet within the inferior vena cava (arrow).

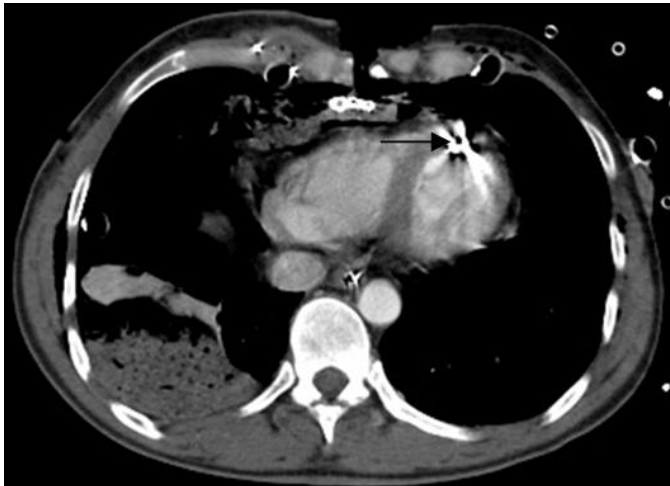

Fig. 4: Contrast enhanced CT of the chest demonstrates a bullet within the left ventricle at risk for arterial embolization.

Attention to missile fragment embolization phenomenon is particularly important in the combat setting (gunshot wounds, IED blast injuries). Once a patient has been stabilized according to Advanced Trauma Life Support protocols, all missile entrance and exit sites should be identified. If no obvious exit site is identified, and no missile fragment is visualized on initial imaging studies, fragment embolization should be considered.¹¹

In a review of 153 patients with missile (bullet) embolization, Michelassi *et al* found arterial missile embolization to be symptomatic in 80% of cases compared to 33% in cases of venous embolization.¹² Complications of fragment embolization generally include vascular occlusion (with consequent organ or limb infarction), thrombus formation, vascular perforation, cardiac arrhythmia, valvular dysfunction, septicemia, and lead toxicity.

When an embolized missile fragment is identified, the risks and benefits of retrieval vs. conservative management are considered. While it is widely accepted that an embolized foreign body causing vascular insufficiency should be removed, there is no consensus on the appropriate management of asymptomatic patients. There have been reports of percutaneous endovascular retrieval of venous bullet emboli; however, there has been only one case of successful endovascular-assisted bullet retrieval in the setting of arterial bullet embolism.¹¹ Typically the treatment of arterial bullet embolization has been via direct surgical extraction.¹²

Bullet emboli to the cerebral arteries are typically not amenable to endovascular removal as there is a risk of intimal injury to the more proximal intracranial vasculature. Management options include direct surgical extraction vs conservative management. Da Costa *et al* suggested that in cases of intracranial vascular missile embolization conservative management be used for asymptomatic patients, and patients with established infarcts or improving neurological symptoms.⁶

While missile embolization is rare, other types of embolized foreign bodies (catheter fragments, wires, stents) are more commonly encountered (figs. 5-7).

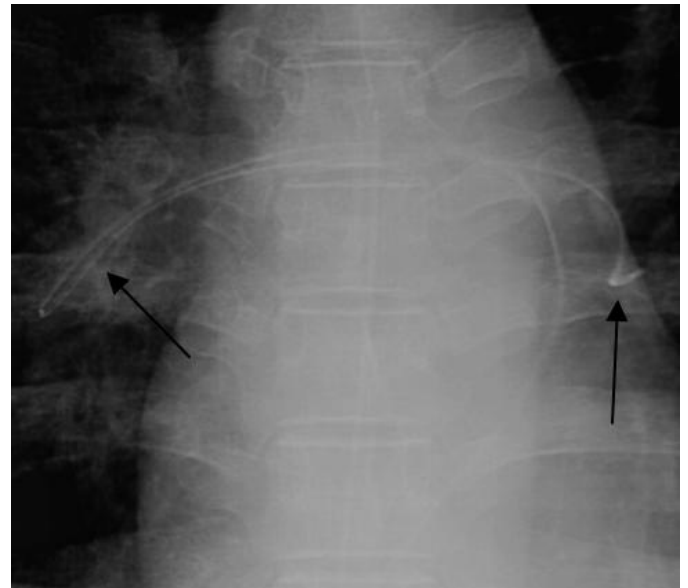


Fig. 5: Frontal chest radiograph demonstrating an embolized PICC line in the pulmonary artery (arrows).

The population at risk for central venous catheter fragmentation and embolization has grown over the years as

central venous access has become more common (parenteral nutrition, chemotherapy).

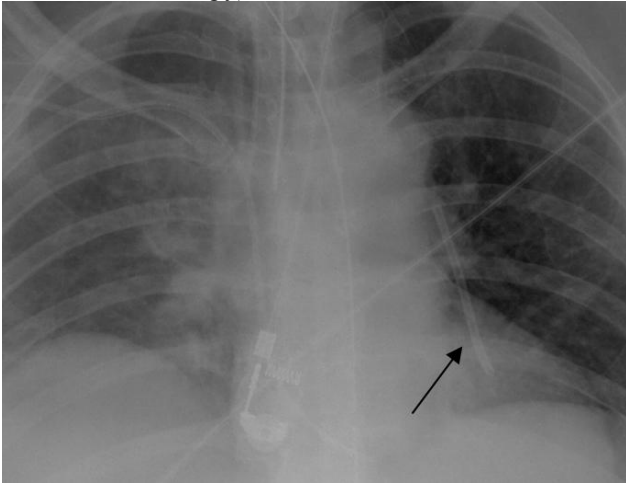


Fig 6a: Coned down frontal chest radiograph demonstrating a catheter fragment projecting in the left pulmonary artery (arrow).

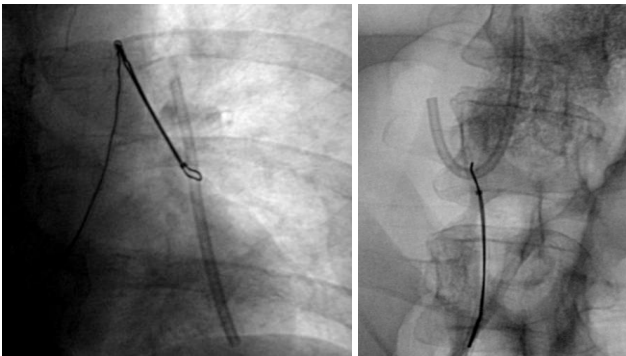


Fig. 6b: Successful snare retrieval of the left pulmonary arterial catheter fragment (seen in fig. 6a).

Causes for catheter fragmentation include catheter damage during placement, fatigue of the catheter material, repetitive catheter movement leading to breakage, and pinch-off syndrome (a phenomenon where a subclavian venous catheter becomes compromised by the mechanical forces acting on it between the clavicle and the first rib).¹³

There have been several publications advocating immediate removal of embolized catheter fragments. In one of the largest studies of unremoved catheter fragments, Fisher and Ferreyro described a 71% incidence of complications including cardiac arrhythmia, sepsis, thrombotic complications (pulmonary embolism, arterial emboli).¹⁴ However, the decision to extract foreign bodies should be individualized based on location and the risk of possible complications.¹³

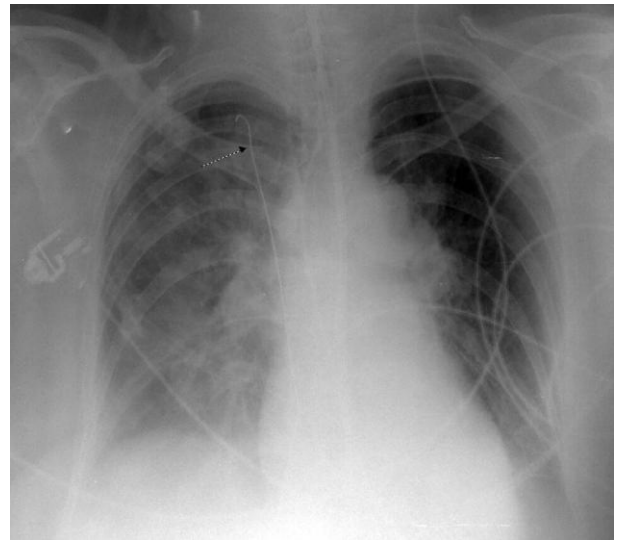


Fig 7: PA chest radiograph demonstrating an embolized guide wire (arrow) from an attempt at femoral venous line access. Note that the tip of the wire is projecting in expected location of superior vena cava.

In addition to catheter fragments, there have been many reports documenting embolization of malpositioned stents, sheath components, guide wires (Fig 7), venous filters and embolic coils.¹⁵⁻¹⁹ Retrieval options include use of snares and baskets for direct removal, or repositioning of the fragment for easier surgical removal. The evolution of baskets, snare loop catheters, special wires, and large-caliber introducer sheaths continues to improve percutaneous endovascular retrieval of foreign bodies.

Summary

Familiarity with the diagnosis and treatment of embolized foreign bodies is important in the combat setting. Missile fragments may be seen both in arterial and venous vessels, and careful detection and localization is important as foreign body removal may improve outcomes. While the treatment for intracerebral arterial embolism remains controversial, percutaneous endovascular retrieval is considered by many to be the standard of care for a wide gamut of venous and arterial foreign body emboli.

Category 1 CME or CNE can be obtained on MedPix™ digital teaching file on similar cases on the following link Many radiology corner articles are also MedPix™ cases of the week where CME credits may be obtained.

<http://rad.usuhs.mil/amsus.html>

References

- 1) Bertoldo U, Enrichens F, Comba A, et al. Retrograde venous bullet embolism: A Rare occurrence – Case report and literature review. J Trauma July 2004; Vol 57(1), 187-192.
- 2) Rich NM, Collins GJ, Anderson CA et al. Missile emboli. J Trauma. 1978; 18: 236-239.
- 3) Cogbill T, Sullivan H. Carotid artery pseudoaneurysm and pellet embolism to the middle cerebral artery following a shotgun wound of the neck. J Trauma, 1995; 39(4): 763-767.
- 4) Gipe BT, Aker B, Smith R. Delayed cerebral embolization of a shotgun pellet with fatal consequences. J Trauma, 1981; 21(4): 326-329.
- 5) Stein M, Mirvis SE, Wiles CE III. Delayed embolization of a shotgun pellet from the chest to the middle cerebral artery. J Trauma 1995;39:1006-09.
- 6) Da Costa LB, Wallace MC, Montanera W. Shotgun pellet embolization to the posterior cerebral circulation. Am J Neuroradiol 2006; 27:261–263.
- 7) Patel KR, Cortes LE, Semel L, et al. Bullet embolism. J Cardiovasc Surg (Torino) 1989; 30: 584-90.
- 8) Adegboyega P, Sustento-Reodica N, Adesokan A. Arterial bullet embolism resulting in delayed vascular insufficiency: A rationale for mandatory extraction. J Trauma 1996; 41(3): 539-54.
- 9) Schurr M. Paradoxical bullet embolism: case report and review of literature. J Trauma. 1996; 40: 1034-1036.
- 10) Corbett H, Paulsen E, Smith S et al. Paradoxical bullet embolus from the vena cava: A case report. J Trauma 2003; 55: 979-981.
- 11) Reil T, Dorafshar A, Lane J et al. Gunshot wound to the left ventricle with bullet embolization to the descending aorta: Combined endovascular and surgical management. J Trauma 2005; 59(4): 1012-1017.
- 12) Michelassi F, Pietrabissa A, Ferrari M, et al. Bullet emboli to the systemic and venous circulation. Surgery. 1990; 107: 239-45.
- 13) Nellore A, Trerotola S. Delayed migration of a catheter fragment from the left to the right pulmonary artery. J Vasc Interv Radiol 2004; 15(5), 497-499.
- 14) Fisher RG, Ferreyro R. Evaluation of current techniques for nonsurgical removal of intravascular iatrogenic foreign bodies. AJR 1978; 130: 541-548.
- 15) Egglin T, Dickey K, Rosenblatt M et al. Retrieval of Intravascular Foreign Bodies: Experience in 32 cases. AJR 1995; 164: 1259-1264.
- 16) Liu JC, Tseng HS, Chen CY et al. Percutaneous retrieval of intravascular foreign bodies: experience with 19 cases. Kaohsiung J Med Sci 2002; 18(10): 492-9.
- 17) Cotroneo AR, Di Stasi C, Pediceli A et al. Percutaneous retrieval of intravascular foreign bodies. Radiol Med 1998; 96(5):492-7.
- 18) Nellore A, Trerotola S. Delayed migration of a catheter fragment from the left to the right pulmonary artery. J Vasc Interv Radiol 2004; 15(5), 497-499.
- 19) Fisher RG, Ferreyro R. Evaluation of current techniques for nonsurgical removal of intravascular iatrogenic foreign bodies. AJR 1978; 130: 541-548.