

Radiology Corner

Mycobacterium Xenopi Found Incidentally on MRI of the Cervical Spine

Guarantor: Chris Walker¹

Contributors: Chris Walker;¹ Col Les Folio, USAF, MC, SFS²

Note: This is the full text version of the radiology corner question published in the November 2009 issue, with the abbreviated answer in the December 2009 issue.

The authors present a case of a 44 year old healthy pregnant (with twins) female diagnosed with *Mycobacterium xenopi* in her lung. A mass was incidentally noted in the right upper apex on an MRI ordered to evaluate a subluxation seen in her cervical spine appreciated on plain radiography. *Mycobacterium xenopi* is uncommon, especially in immunocompetent patients. The patient did have a fractured ankle while pregnant. This case highlights importance of recognition of findings included in the field of view of an exam, even if not directly related to the study region of interest; in this case a cervical spine MRI with a positive finding within the lung apex.

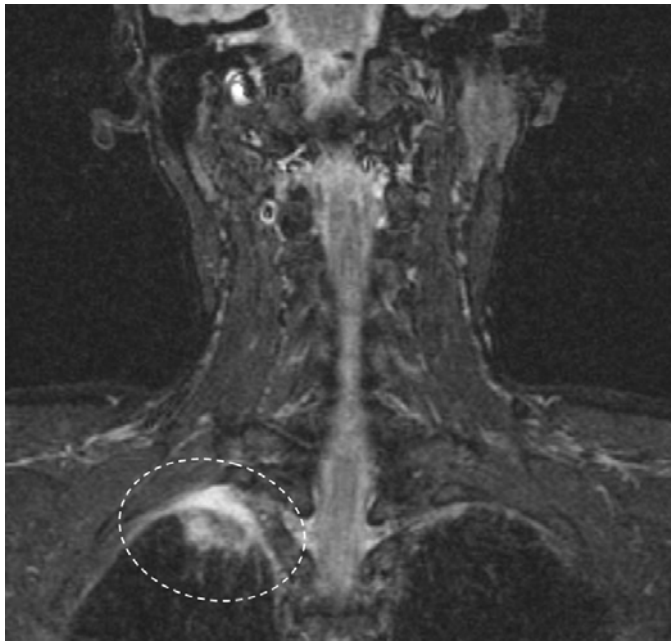


Fig. 1 MRI ordered for cervical spine with incidental finding of right upper lung mass (dotted circle). This speculated area of increased signal explained the Pancoast tumor-like symptoms and led to the eventual diagnosis of *M. Xenopi*.

¹ School of Medicine, Uniformed Services University of the Health Sciences, Bethesda, Maryland 20814-4799

² Department of Radiology and Radiological Sciences; Uniformed Services University of the Health Sciences, Bethesda, Maryland 20814-4799

Reprint & Copyright © by Association of Military Surgeons of U.S., 2006.

History:

Our patient was five months pregnant with twins when she fell and broke her right foot in the spring of 2007. Around that time, she developed numbness of the right arm and pain in right scapular/shoulder region. Symptoms were attributed to pregnancy (fluid and swelling), however, symptoms got progressively worse even after the twins were born in July 2007.

By the fall of 2007, the symptoms had progressed to more systemic manifestations: fatigue; night sweats; rash; numbness in right hand and arm; pain with movement of arms or wrists; pain and stiffness in lower back, hips, calves; burning pain and numbness of feet with difficulty walking; weakness in arms and legs; and muscle fatigue.

Despite extensive use of a wide variety of NSAIDs and several weeks of physical therapy for the presumed diagnoses of bilateral plantar fasciitis, bilateral shoulder tendinitis and bilateral tenosynovitis of wrists, there was no improvement of patient's symptoms.

The patient had numbness in right arm (particularly in median nerve distribution). This clinical finding may have been related to the mass itself, which was deeply imbedded into the pleura, causing pressure upon the brachial plexus. She also had systemic symptoms: profound fatigue, night sweats, and maculopapular rash on anterior thighs.

Summary of Findings:

On further workup, the patient was found to have a subluxation of C3 on C4, seen on x-ray of c-spine (only on extension lateral view). Even though the subluxation was not particularly pronounced, it was determined to be the probable cause of the patient's pain, numbness and weakness in the arms and legs. More importantly, however, the cervical spine MRI incidentally revealed a large mass in the upper lobe of the right lung (fig 1). The mass measured almost 3cm and appeared to invade the pleura (see fig 2 for CT).

Patient discussion:

Although the patient had no smoking history, lung cancer was a concern. Given that the patient had initially presented with right arm numbness and shoulder pain, the mass was suspicious for a Pancoast tumor.

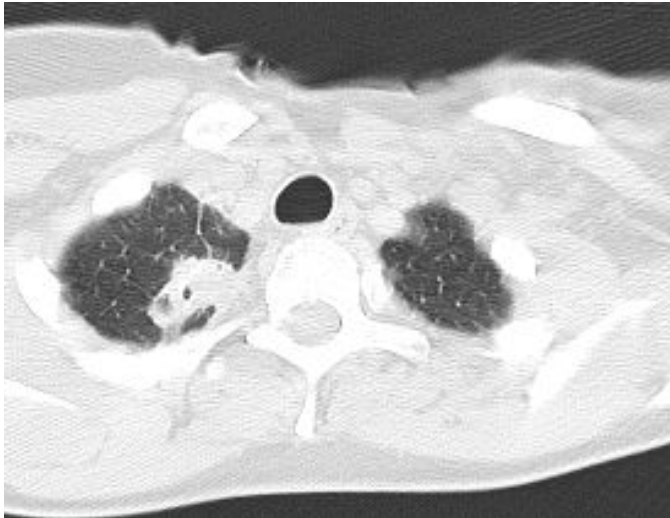


Fig. 2 Note the ovoid mass in the right lung apex with lucent areas within indicating cavitation. Note pleural involvement and associated interstitial markings on right.

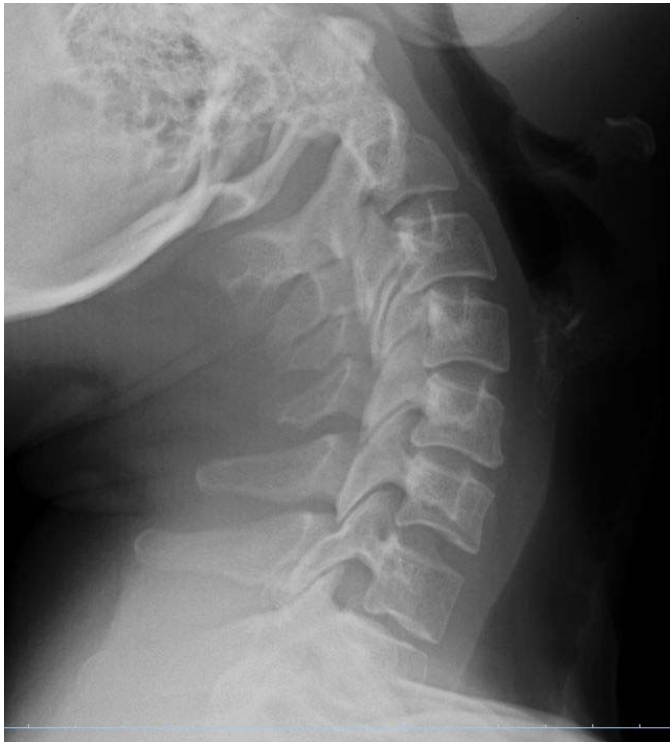

Fig. 3. Extension lateral c-spine with retrolithesis of C3-C4.

definitive way, and there was no evidence of metastatic disease.

Subsequent CT-guided needle biopsy of the mass demonstrated fibrosis, old blood and inflammatory cells, but no malignant cells. The patient had a VATS (Video Assisted Thoracic Surgery) wedge excision of the lung mass. The lung mass turned out to be AFB-positive. Triple-drug therapy was initiated for the treatment of tuberculosis - rifampin, INH, ethambutol, with pyridoxine.

Subsequent testing of the mass with DNA probes, however, could not identify the bacterium. It was *not M. tuberculosis*, nor any of the four most prevalent of the atypical mycobacteria. The tissue was sent to National Jewish Hospital, Denver and finally identified as *M. Xenopi* by DNA probe.

There was no history of penetrating injuries or camping or exotic travel (other than New Zealand and Fiji). The patient may have contracted during her surgical residency - the hospitals she trained in NYC were fairly old. *M. xenopi* has been found to colonize the steam outlet valves of hospital hot water heaters. The cervical spine findings, although real, were not the root cause of the symptoms in this patient. See figures 3 and 4 for plain cervical spine

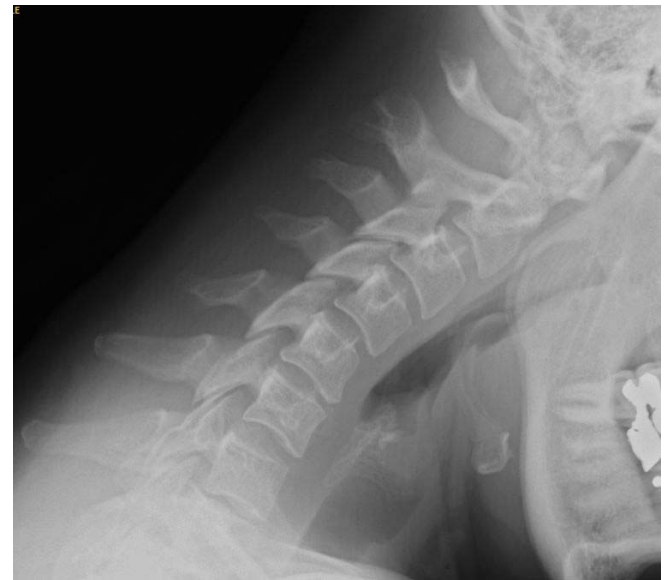

Fig. 4. Flexion lateral c-spine, neutralizing the subluxation seen on extension lateral.

Diagnosis *Mycobacterium xenopi*

The only other significant pulmonary history was that two years earlier, the patient had had a four month-long respiratory illness associated with severe fits of coughing, malaise and fatigue. This had been diagnosed as pertussis, which is a diagnosis of exclusion. A PET scan was obtained and showed the RUL mass to uptake radiopharmaceutical, but not in a

She was admitted to the NIH for four days in June 2008 for further workup of immunocompromised conditions. She had a follow-up chest CT in June and again in September 2008, which demonstrated only mild bronchiectasis.

The systemic symptoms (fatigue, night sweats) began to improve within one month of starting antibiotic therapy. She will complete a one-year course. The pain, numbness, stiffness took much longer to improve. Current therapy to manage the neuropathic pain in the feet is Neurontin 900 mg TID, Naproxen 500 mg BID, Zanaflex 4mg QD, and Cymbalta 60

mg BID. As of now the patient is feeling great and doing well. This case represents the symptoms and relief of symptoms with treatment characteristic of the disease.

This case report highlights the importance of incidental findings included within the field of view of studies ordered with other regions of interest in mind. In addition, *M. xenopi* is relatively rare, especially in immunocompetent individuals.

Discussion

Mycobacterium xenopi is a nontuberculous mycobacterium (NTM) that has been isolated from environmental water and soil samples, as well as tap-water systems even in hospital hot water sources.¹ Since infection usually occurs in the lungs, transmission is thought to be most likely due to inhalation of airborne particles, but evidence points to water point sources. Person-to-person transmission has not been documented. Typically thought to be an opportunistic pathogen in immunocompromised patients such as those with HIV, *M. xenopi* has recently been demonstrated to infect immunocompetent individuals.² These individuals usually have some chronic health disorder as a risk factor for infection. The major associated risk factor is COPD; others include diabetes mellitus, alcoholism, and cancer.

Actual cases present with symptoms characteristic of the disease, while colonizations are found in asymptomatic individuals incident to CT scans for other reasons. The following are summaries of relevant cases:

In Andrejak et al, all of the cases in immunocompetent patients presented with a solitary nodule rather than multifocal nodular densities or lesion indicating no further spread.³

Traboulsi et al, presents the first documented case of disease in an immunocompetent individual, although since the patient was asymptomatic, did not technically meet all of the American Thoracic Society diagnostic criteria (does not meet clinical signs and symptoms, but still meet radiographic and microbiological). They did isolate the organism and were able to culture it though, which they argue is good enough for diagnosis.⁴

Marusic et al. conducted a retrospective study in which they found 40 patients with colonizations of *M. xenopi*, and 24 met the diagnostic criteria set forth by the American Thoracic Society for pulmonary disease.⁵ Also notable here is that the epidemiology differs geographically. *M. xenopi* is the most frequent NTM isolate in Croatia and quite frequent in other parts of Western Europe, while it is not nearly as frequent in the United States.

In terms of common radiographic findings, Wittram and Weisbod published the results, "Eight immunocompetent patients fulfilled the American Thoracic Society criteria for *M. xenopi* infection and had CT scans of the thorax." Results showed: Seven patients demonstrated upper lobe cavitory

disease: one cavitory mass, one cavitory nodule, three consolidations with multiple cavities, and two cavities only. One patient demonstrated upper lobe consolidation only."⁶

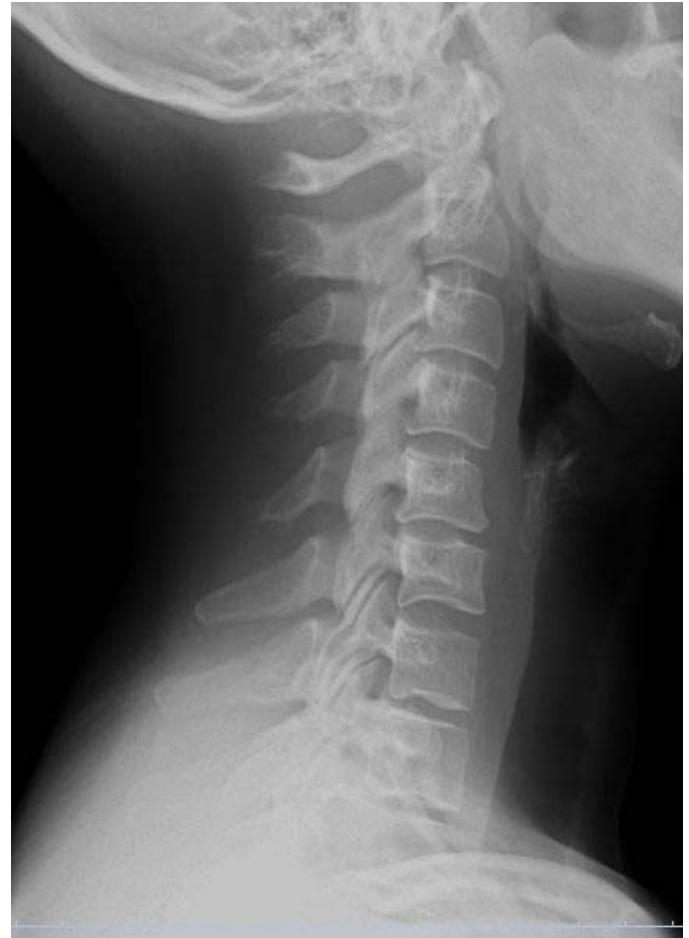

Fig. 5. Neutral lateral cervical spine with straitening, likely due to positioning and/or spasm.

M. xenopi has been increasingly documented, most notably in immunocompetent patients such as the patient in this case. The respiratory symptoms from two years prior fit within normal expectations, yet the secondary onset of symptoms presented here are atypical. The patient is immunocompetent but does not have any underlying health disorder. It was considered that pregnancy with twins could have compromised our patient, especially compounded with twins and a traumatic event. Initial colonization could have come from a contaminated water source in a hospital in which the patient worked. Importantly, diagnosis was possible through recognition of a finding not included in the initial area of interest.

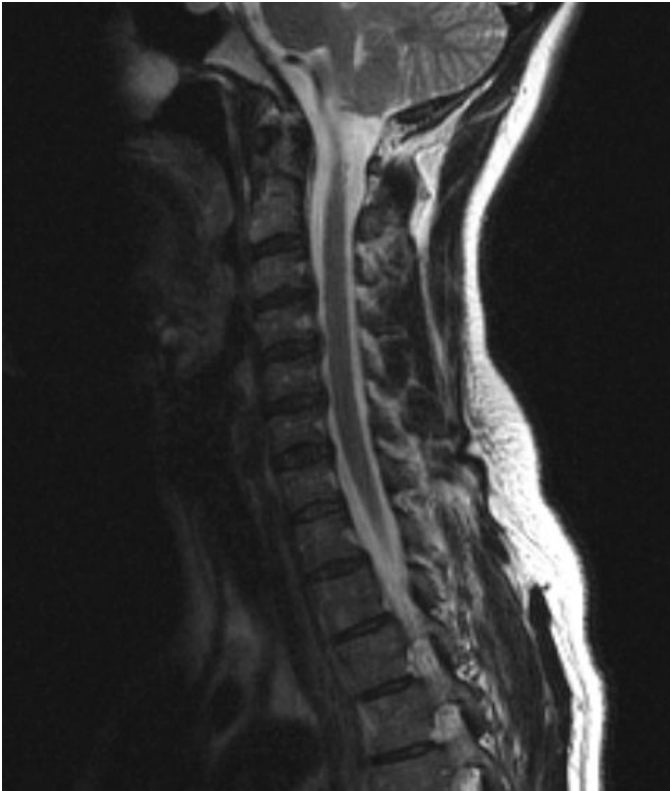

Fig. 6. Sagittal T2 weighted MR showing discs bulges at C3-4 through C5-6, without evidence of frank herniation.

Category 1 CME or CNE can be obtained on the MedPix™ digital teaching file on similar cases by opening the following link. Many Radiology Corner articles are also a MedPix™ Case of the Week where CME credits can be obtained.

<http://rad.usuhs.mil/amsus.html>

References

- ¹ Falkinham JO III. Epidemiology of infection by nontuberculous mycobacter. *Clin Microbiol Rev* 1996;9:177-215.
- ² Marusic A et al. *Mycobacterium xenopi* pulmonary disease – Epidemiology and clinical features in non-immunocompromised patients. *J Infect* (2009), doi:10.1016/j.inf.2009.01.001
- ³ Andrejak C, Lescure FX, Pukenyte E, Douadi Y, Yazdanpanah Y, Laurans G, Schimit JL, Jounieaux V. *Mycobacterium xenopi* pulmonary infections: A multicentric retrospective study of 136 cases in North East France. Clinical and radiological features, treatment and outcome. *Thorax*. 2008 Dec 3. [Epub ahead of print]
- ⁴ Traboulsi R, Kanafani ZA, Hourani M, Kanj SS. Asymptomatic *Mycobacterium xenopi* lung abscess in an immunocompetent man without pre-existing lung pathology. *Scandinavian Journal of Infectious Diseases*. 2005 August 8.
- ⁵ [No authors listed]. Diagnosis and treatment of disease caused by non-tuberculous mycobacteria. This official statement of the American Thoracic Society was approved by the Board of Directors, March 1997. Medical Section of the American Lung Association. *Am J Respir Crit Care Med* 1997;156:S1-25.
- ⁶ Wittram C, Weisbrod GL. *Mycobacterium xenopi* pulmonary infection: Evaluation with CT. *J Comput Assist Tomogr* 1998;22:225-228.