

Radiology Corner

Noncardiogenic Pulmonary Edema as a Result of Urosepsis

Guarantor: 2LT Robert Vietor, MSC, USA¹

Contributors: 2LT Robert Vietor, MSC, USA¹; COL Les Folio, MC, USAF, SFS¹

Note: This is the full text version of the radiology corner question published in the February 2010 issue, with the abbreviated answer in the March 2010 issue.

The authors present the case of a patient with noncardiogenic pulmonary edema as a result of urosepsis. We explain the physiologic and radiographic differences between cardiogenic and noncardiogenic pulmonary edema. We also discuss some specific types of pulmonary edema and the radiographic findings that are commonly present. In addition, we define sepsis and the physiologic effect that it has on the alveolar-capillary membrane of the lung. Since Acute Respiratory Distress Syndrome is a major cause of noncardiogenic pulmonary edema, we also explore this pathologic process and look at some of the possible complications of ARDS. Finally, the challenges in the treatment of cardiogenic and noncardiogenic pulmonary edema and the importance of early diagnosis and appropriate intervention are addressed.

Introduction

An 84-year-old male presented to the emergency department with lethargy, dehydration, pallor and right upper quadrant pain. His medical history is significant for chronic pyuria, hypertension, chronic obstructive pulmonary disease and dementia. Blood pressure on presentation was 96/58, heart rate was 126 beats per minute and temperature was 98.6 F. On pulmonary exam the patient had crackles in the anterior and posterior lung fields, which were most pronounced in the posterior basilar segments. Laboratory analysis of urine revealed a urinary tract infection (UTI). Complete Blood Count (CBC) showed a white blood cell (WBC) count of 24,000 cells/mm³. AP Chest radiographs were obtained on day 1 (Fig. 1A) and day 2 (Fig. 1B) of hospitalization.

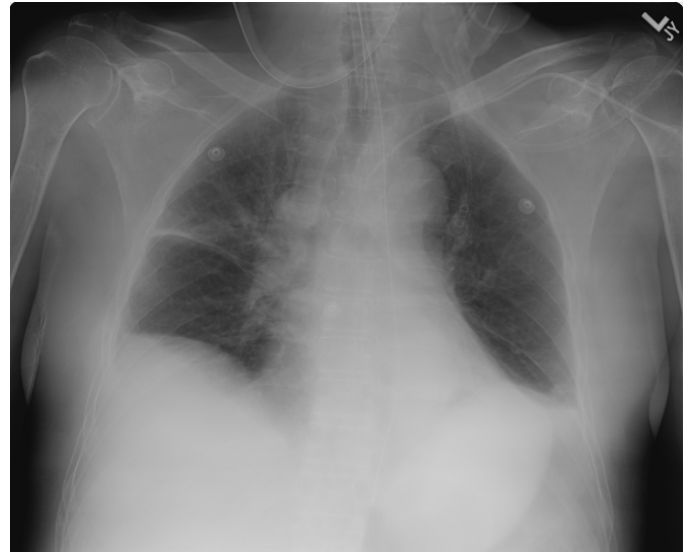

Fig. 1A. Chest radiograph from hospital day one shows lungs that are adequately inflated with bilateral costophrenic angle blunting representing small pleural effusions. Right lung fissure thickening represents fluid.

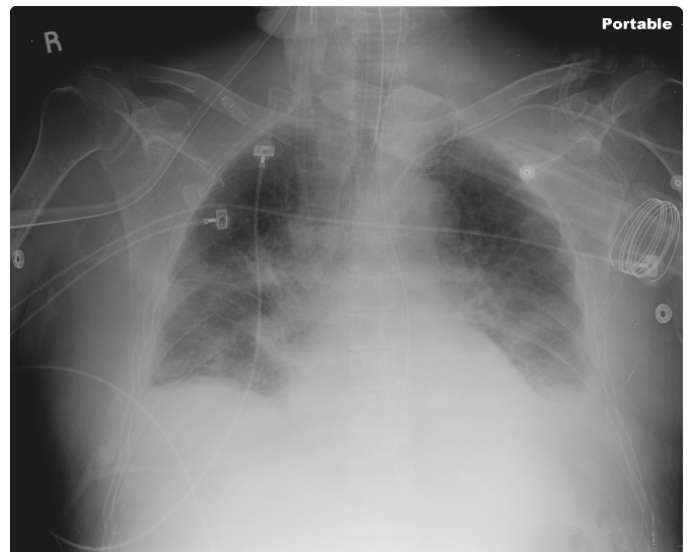


Fig. 1B. Chest radiograph from hospital day two shows bibasilar patchy opacities along with left greater than right small pleural effusions and edema. This image is significant for enlarged and indistinct hila with a blurring of the outline of the pulmonary vessels (which normally have sharp borders on chest radiograph). These findings are consistent with pulmonary edema.

¹ Department of Radiology and Radiological Sciences; Uniformed Services University of the Health Sciences, Bethesda, Maryland 20814-4799.

Reprint & Copyright © by Association of Military Surgeons of U.S., 2010.

Summary of Imaging Findings

On hospital day 1, a portable AP chest radiograph (Fig. 1A) was obtained. The radiograph reveals lungs that are adequately inflated with bilateral costophrenic angle blunting representing small pleural effusions. In addition there is right lung fissure thickening, which is most likely fluid. These findings suggest pulmonary edema. Another portable chest radiograph was obtained on hospital day 2 (Fig. 1B). This image again shows bibasilar consolidations along with left greater than right small pleural effusions and edema. There are enlarged and indistinct hila with blurring of the pulmonary vessel outlines, which normally appear as sharp borders on chest radiograph. These additional findings support a diagnosis of pulmonary edema.

Patient Discussion

In addition to the radiographic findings suggestive of pulmonary edema, there were important physical exam and lab findings that led to the diagnosis of urosepsis. First were the vital signs. The patient had a heart rate of 126 and a blood pressure of 96/58, which could be attributed to a number of causes such as sepsis, dehydration, hemorrhage, or myocardial infarction. Next, was the CBC. It showed a WBC count of 24,000 cells/mm³ which made the diagnosis of sepsis much more likely but there still needed to be a source of infection. This was provided by the urinalysis which uncovered a UTI. With a source of infection found, a WBC count greater than 12,000, and tachycardia the criteria for a diagnosis of sepsis was met and the patient was treated appropriately.

After receiving 1 liter of normal saline in the emergency department the patient was admitted to the hospital for fluid resuscitation. In order to treat the sepsis the patient was placed on IV antibiotics for 14 days. He was given pressors for blood pressure control and was intubated due to increasing pulmonary distress. The patient remained on ventilator support until hospital day 10 at which time his WBC count began trending downwards, his respiratory status showed improvement, and he was having appropriate diuresis.

Diagnosis:

Noncardiogenic Pulmonary Edema as a Result of Urosepsis

Discussion

Pulmonary edema is caused by the movement of excess amounts of fluid into the alveoli of the lungs. When pulmonary edema is the result of elevated pulmonary capillary pressure, the edema is referred to as cardiogenic. Cardiogenic pulmonary edema is usually the result of left ventricular diastolic or systolic dysfunction. Left ventricular dysfunction can occur due to many processes such as aortic or mitral valve dysfunction, coronary artery disease or cardiomyopathy. In contrast to cardiogenic pulmonary edema, noncardiogenic pulmonary edema is pulmonary edema caused by a pathologic process other than elevated pulmonary capillary pressure (1).

Typically noncardiogenic pulmonary edema is due to increased permeability of the alveolar-capillary membrane. Common causes include infectious septicemia, inhalation of toxic gases and high altitude disease.

Cardiogenic vs. noncardiogenic pulmonary edema:

Chest radiography can be useful in the diagnosis of cardiogenic and noncardiogenic pulmonary edema. If fluid accumulation is present on chest radiograph and there is an absence of elevated pulmonary capillary pressure, a physician can make the diagnosis of noncardiogenic pulmonary edema. Interestingly, even in the absence of pulmonary capillary pressure measurements, some radiologists can distinguish between the two causes of pulmonary edema in over 90% of cases (2). One important radiological difference is in the appearance of the heart and pulmonary vasculature. In noncardiogenic pulmonary edema cardiac size, vascular pedicle width and pulmonary blood volume are normal. However in cardiogenic pulmonary edema the heart is typically enlarged, the vascular pedicle width is increased and the distribution of blood flow in the lung is inverted.

A second radiographic distinction is that Kerley lines are never seen in noncardiogenic pulmonary edema, but they are a common finding in cardiogenic pulmonary edema. If Kerley lines are found in noncardiogenic edema, then cardiogenic edema is also present and the patient most likely has mixed cardiogenic and noncardiogenic edema. In noncardiogenic pulmonary edema the edema appears predominately as alveolar filling. This occurs because the disrupted alveolar-capillary membrane allows for proteinaceous fluid to accumulate in the air spaces and this fluid cannot be cleared via the interstitium due to the high protein content. This is different from cardiogenic edema because the filling of airspaces in cardiogenic edema does not occur until the interstitial space is overwhelmed.

Finally, a patchy or peripheral pattern of edema is more common in noncardiogenic edema, while the edema is central and pleural effusion usually coexists in cardiogenic edema. The radiographic distinctions above are most useful in mild cases of pulmonary edema. Distinguishing between the two types of pulmonary edema in severe cases is much more difficult with radiographic imaging alone (3).

Causes of pulmonary edema and associated findings:

In addition to the above general differences between cardiogenic and noncardiogenic pulmonary edema, there are some specific causes of pulmonary edema that have distinct radiographic findings. First is “**Batwing**” edema which is seen in less than 10% of patients with pulmonary edema. It usually occurs in the setting of severe cardiac or renal failure. It is typically a central, nongravitational distribution of pulmonary edema with sparing of the lung cortex (4).

Next is **postobstructive** pulmonary edema which occurs after an object obstructing the upper airway is removed, resulting in a sudden drop in intrathoracic pressure. On radiography the edema will manifest as septal lines,

peribronchial cuffing and sometimes central alveolar edema will be present (5). The edema typically resolves within 2 – 3 days.

Pulmonary **veno-occlusive disease** is another cause of pulmonary edema. It is caused by thrombi that narrow small pulmonary veins and venules. In addition to edema the patient may present with dyspnea or hemoptysis. Kerley lines, peribronchial cuffing, diffuse interstitial edema, enlarged pulmonary arteries and a dilated right ventricle can be seen on radiography (6).

One important cause of pulmonary edema is **high altitude** pulmonary edema because it frequently occurs in otherwise healthy individuals and can lead to death without appropriate treatment. Frequently this process will show central interstitial edema with peribronchial cuffing, ill-defined vessels, and a patchy airspace consolidation. In severe cases the patchy consolidation can become confluent and involve the entire lung parenchyma. Occasionally Kerley lines may also be present (7).

A common, but difficult to diagnose cause of pulmonary edema is **neurogenic** pulmonary edema. It is present in up to 50% of patient with brain injury. The injury can be the result of trauma, stroke or even seizures. It is difficult to differentiate this form of pulmonary edema from other causes, therefore it is often a diagnosis of exclusion. The patient will present with dyspnea, tachypnea and cyanosis. Chest radiograph will show bilateral, homogenous airspace consolidations, which is frequently more noticeable in the apices of the lungs (8). In neurogenic pulmonary edema the patient's prognosis is usually determined by the underlying brain injury and not the pulmonary edema.

In the patient's case discussed above, he was suffering from noncardiogenic pulmonary edema as a result of **sepsis**. Sepsis is a common cause of pulmonary edema (9). In this case, the patient had urosepsis which is caused by an infection in the urinary tract that spreads to the blood stream. Sepsis in a patient is defined as the presence of at least two of the following in addition to a culture proven infection or an infection identified on visual inspection (10):

- Temperature $>38.5^{\circ}\text{C}$ or $< 35.0^{\circ}\text{C}$,
- Heart rate > 90 beats/min
- Respiratory rate > 20 breaths/min or $\text{PaCO}_2 < 32$ mmHg
- WBC $>12,000$ cells/mm³, <4000 cells/mm³, or > 10 percent immature forms.

In sepsis and many other forms of noncardiogenic pulmonary edema, interstitial and alveolar edema are caused by endothelial injury in the pulmonary vasculature. The injury leads to a disturbance of capillary blood flow and an increase in microvascular permeability. Entrapment of neutrophils in the lung's microcirculation can enhance the injury to the alveolar-capillary membrane (11). These processes give rise to clinically significant symptoms and provide the radiographic changes associated with pulmonary edema. The pulmonary edema then causes a ventilation-perfusion

mismatch leading to arterial hypoxemia. The reason the lungs are injured so frequently in sepsis is because the lungs have a high microvascular surface area (12). In some cases severe sepsis can progress to acute respiratory distress syndrome (ARDS).

ARDS is a major cause of noncardiogenic pulmonary edema and the most common cause of ARDS is sepsis. It is important to realize that noncardiogenic pulmonary edema and ARDS are not the same pathological entity. Noncardiogenic pulmonary edema is almost always present at the onset of ARDS, but many cases of pulmonary edema never progress to the severe state of respiratory impairment needed to meet the criteria for ARDS (13). ARDS is characterized by the following:

- Acute onset of symptoms
- Bilateral infiltrates on chest radiograph
- Pulmonary artery wedge pressure less than 18 mmHg
- $\text{PaO}_2:\text{FiO}_2$ less than 200 mmHg (14).

ARDS typically has an acute onset and develops within 4 – 48 hours, but can last for days to weeks (15). Like sepsis, ARDS can cause a ventilation-perfusion mismatch along with physiologic shunting. ARDS can also cause decreased lung compliance. This is due to the stiffness of the lung tissue not receiving air. Since only the functioning portions of the lung can allow gas exchange, the inspiratory capacity of the lungs is severely diminished (16). In addition, pulmonary hypertension can develop in ARDS patients who are on mechanical ventilation. The most significant hemodynamic consequence of pulmonary hypertension is cor pulmonale. Fortunately the occurrence of cor pulmonale in these patients is rare (17).

Three pathologic stages are frequently seen in ARDS. The first is referred to as the exudative stage and is characterized by diffuse alveolar damage that progresses into the second stage called the proliferative stage. This stage is marked by the resolution of pulmonary edema. The proliferative stage also shows early deposition of collagen, squamous metaplasia, proliferation of type II pneumocytes, and infiltration of myofibroblasts. Not all patients progress to the third phase. The third phase is called the fibrotic phase during which normal lung architecture is obliterated, diffuse fibrosis occurs and cyst formation is present (18). As of 2006 the mortality rate for patients with ARDS was 25 - 30%. This is a great improvement from the 1990 mortality rate of 67%. The increased survival is most likely due to improvements in supportive care (19).

It is important to realize that in order to treat any type of pulmonary edema the underlying pathology must be determined and corrected. In cardiogenic pulmonary edema the underlying cause could be aortic stenosis, which may require surgery to correct, or it could be coronary artery disease, which can be treated through a variety of methods such as lifestyle changes, LDL lowering medications or bypass surgery. In the case of noncardiogenic pulmonary edema due to urosepsis, treatment would include broad spectrum antibiotics to eliminate the infection and surgical

drainage of any abscesses present, but in contrast the treatment for high altitude pulmonary edema consists of acetazolamide and dexamethasone. Both of these processes create a noncardiogenic pulmonary edema, but they require much different treatments. Unfortunately there is no known treatment that can correct the vascular permeability abnormalities seen in noncardiogenic pulmonary edema and ARDS. In addition to treating the underlying cause of any type of pulmonary edema, supportive measures may be necessary to allow the patient's lungs to recover from the injuries (20). In order to ensure proper exchange of air in the lungs the patient may require intubation and mechanical ventilation. Cardiovascular support for these patients can be complicated. In the case of this patient with sepsis, he required pressors to maintain adequate blood pressure. However, in a patient with inadequate filling of the left ventricle due to diastolic dysfunction, a beta-blocker may be necessary to allow for filling of the ventricle and provide blood flow to the myocardium. In addition, adequate nutrition and fluid management are important in all patients. Fluid management can be difficult; too much fluid can increase the edema in the lungs.

Based upon the pulmonary capillary pressure, pulmonary edema can be broken down into two causes; cardiogenic and noncardiogenic. These categories encompass a wide array of pathological processes and can cause morbidity and even mortality in a patient. Therefore it is important to diagnose pulmonary edema early and use radiographic techniques in addition to patient history, physical exam findings and lab tests in order to find the source of the pulmonary pathology and treat the patient appropriately.

Note: Follow this link for Category 1 CME or CNE in the case of the week in the MedPix™ digital teaching file.

<http://rad.usuhs.mil/medpix/medpix.html>

References

1. Ware LB, Matthay MA: Clinical practice: Acute pulmonary edema, *New Engl J Med* 2005; 353:2788.
2. Milne N, Pistolesi M, Miniati M: The radiographic distinction of cardiogenic and noncardiogenic edema, *Am J Roentgenol* 1985;144: 879-894.
3. Aberle R, Wiener P, Webb R: Hydrostatic versus increased permeability edema: Diagnosis based on radiographic criteria in ill patients, *Radiology* 1988; 168:73 – 75.
4. Milne ENC, Pistolesi M: Reading the chest radiograph: a physiologic approach, *Mosby Year Book* 1993; 9 – 50.
5. Ketaj LH, Goodwin JD: A new view of pulmonary edema and acute respiratory distress syndrome: state of the art, *J Thor Imag* 1998; 13:147 – 171.
6. Maltby JD, Gouverne ML: CT findings in pulmonary venoocclusive disease: case report, *J Comput Assist Tomo* 1984; 8:758 – 761.
7. Vock P, Brutsche MH, Nanzer A, Bartsch P: Variable radiomorphologic data of high altitude pulmonary edema: features from 60 patients, *Chest* 1991; 100:1306 – 1311.
8. Ell SR: Neurogenic pulmonary edema: a review of the literature and a perspective. *Invest Radiol* 1991; 26:499 – 506.
9. Martin TR: Lung cytokines and ARDS, *Chest* 1999; 116:2S.
10. Levy MM, Fink MP, Marshall JC, et al: Bacteremia and severe sepsis in adults: A multicenter prospective survey in ICUs and wards of 24 hospitals, *Am J Resp Crit Care* 2003; 31:1250.
11. Luce JM: Pathogenesis and management of septic shock, *Chest* 1987; 91: 883.
12. Ghosh S, Latimer RD, Gray BM, et al: Endotoxin-induced organ injury, *Crit Care Med* 1993; 21:S19.
13. Kollef MH, Schuster DP: The acute respiratory distress syndrome, *New Engl J Med* 1995; 332:27.
14. Bernard G, Artigas A, Brigham K, et al: The American-European consensus conference on ARDS: definitions, mechanisms, relevant outcomes, and clinical trial coordination, *Am J Resp Crit Care* 1994; 149:818–24.
15. Hudson LD, Milberg JA, Anardi D, Maunder RJ: Clinical risks for development of the acute respiratory distress syndrome, *Am J Resp Crit Care Med* 1995; 151:293.
16. Roupie E, Dambrosio M, Servillo G, et al: Titration of tidal volume and induced hypercapnia in acute respiratory distress syndrome, *Am J Resp Crit Care Med* 1995; 152:121.
17. Melot C, Naeije R, Mols P, et al: Pulmonary vascular tone improves pulmonary gas exchange in the adult respiratory distress syndrome, *Am Rev Resp Dis* 1987; 136:1232.
18. Tomaszefski JFJ: Pulmonary pathology of the adult respiratory distress syndrome, *Clin Chest Med* 1990; 11:593.
19. Wiedemann HP, Wheeler AP, Bernard GR, et al: Comparison of two fluid-management strategies in acute lung injury. *New Engl J Med* 2006; 354:2564.
20. Fulkerson WJ, MacIntyre N, Stamler J, et al: Pathogenesis and treatment of the adult respiratory syndrome, *Arch Intern Med* 1996; 156.