# Spinal Neoplasms and Mimics

**James G. Smirniotopoulos, M.D.**
Professor of Radiology, Neurology, Biomedical Informatics
Chair, Radiology and Radiological Sciences
Uniformed Services University
of the Health Sciences
Bethesda, M.D.

james-smirnio@usuhs.mil

Website - rad.usuhs.edu

## Spine Disease Categories

- Congenital malformations
- Trauma
- Degenerative Disease
  - Osteoarthritis, Disk Disease
- Inflammatory
  - Multiple Sclerosis, Transverse Myelitis
- Neoplasms
- Vascular

## Spine Disease Locations

- Intramedullary Lesions
- Intradural – Extramedullary Lesions
  - In the subarachnoid space
- Extradural Lesions
  - Inside the bony neural canal/arch
  - Affecting the bone, disc, ligament
  - Outside the spinal column

## Localization of Spinal Masses

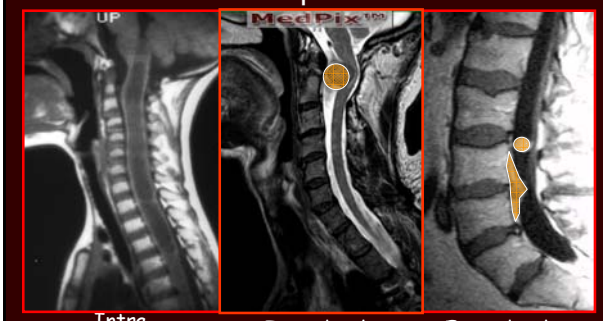


Intra-medullary | Intradural Extra-medullary | Extradural

## Spine - Extramedullary Lesions

- Traumatic
  - Subarachnoid hemorrhage
- Vascular
  - Subarachnoid Hemorrhage
  - Varices
- Inflammatory
  - Meningitis
- Neoplastic
  - Meningioma
  - Schwannoma, Neurofibroma
  - Epidermoid, Dermoid
  - Paraganglioma
  - Metastasis

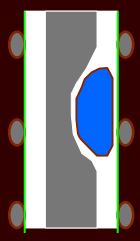

Intradural - Extramedullary

## Spine - Extradural Lesions

- Traumatic
  - Epidural Hematoma
- Vascular
  - Batson's Plexus, Interruption of IVC
  - Vertebral Hemangioma
- Inflammatory
  - Vertebral Osteomyelitis
  - Epidural abscess
- Neoplastic
  - Lymphoma
  - Osteoblastoma, Giant Cell Tumor
  - Lipomatosis
  - Metastases

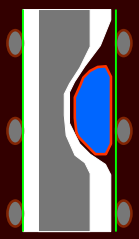

Extradural

## Intradural Intramedullary Tumors

- Ependymoma
- Astrocytoma
- Hemangioblastoma
- Oligodendroglioma
- Metastatic
- Lipoma of filum
- Syringohydromyelia

## Cervical Myelogram

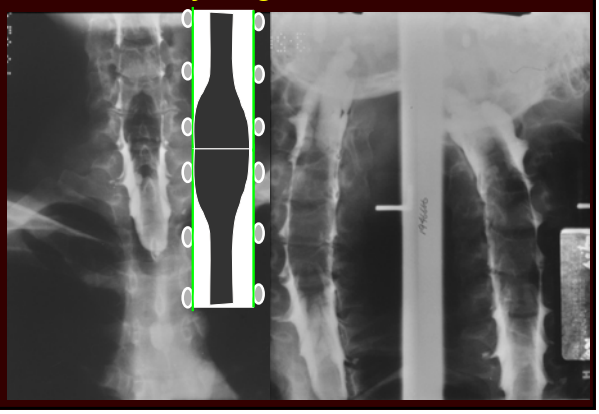

## DDx of EXPANDED CORD

- Primary & Secondary Neoplasms
- Myelitis, Abscess
- Granuloma
- Acute MS
- Syringohydromyelia (primary/secondary)
- Vascular - Infarct, Edema
- Trauma - Hematoma, Contusion, Edema

## Spine - Intramedullary Lesions

- Traumatic
  - Contusion, Edema
- Vascular
  - Ischemia, Hemorrhage
- Inflammatory
  - Demyelination, Myelitis
- Neoplastic
  - **Ependymoma**
  - Astrocytoma
  - Hemangioblastoma
  - Syringohydromyelia

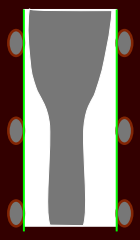

Intramedullary

## EPENDYMOMAS

- 90% of intramedullary neoplasms are gliomas: ependymoma, astrocytoma and oligodendroglioma
- 65% of cord gliomas are Ependymoma
- 60% are in filum (myxopapillary type)
- Ependymoma is slow growing
  - Vascular with blood products – "Hemosiderin Cap"
  - Cystic changes seen often
  - Solid areas enhance homogeneously
  - Well demarcated and resectable

## NEUROLOGIC NEOPLASMS

### Spinal Gliomas



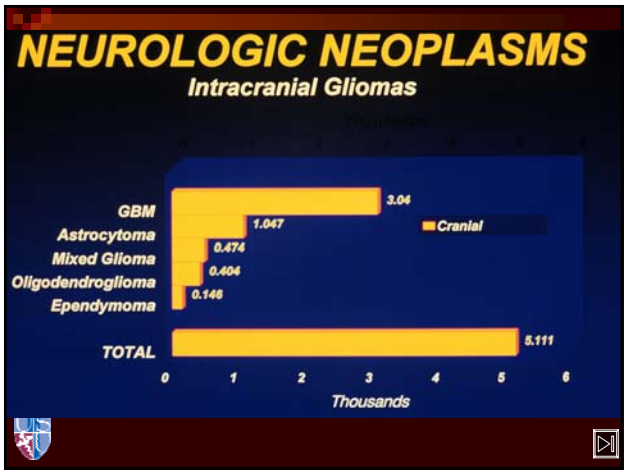
NEUROLOGIC NEOPLASMS
Intracranial Gliomas
GBM
Astrocytoma
Mixed Glioma
Oligodendroglioma
Ependymoma
TOTAL
3.04
1.047
0.474
0.404
0.146
5.111
Cranial
0
1
2
3
4
5
6
Thousands

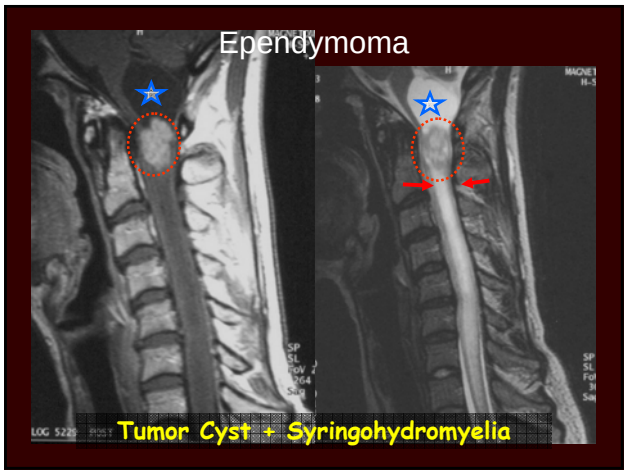
Ependymoma
Tumor Cyst + Syringohydromyelia

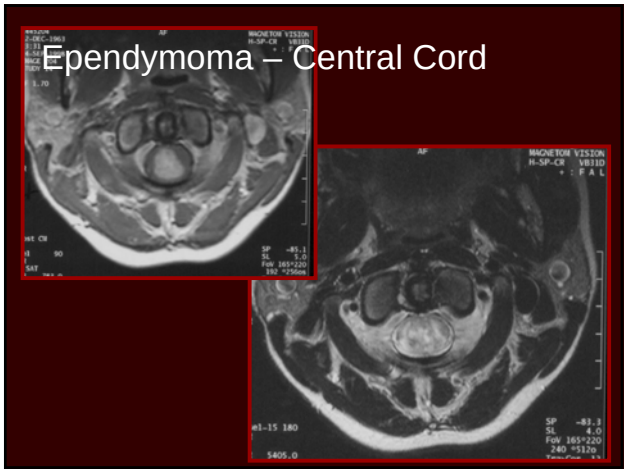
Ependymoma – Central Cord

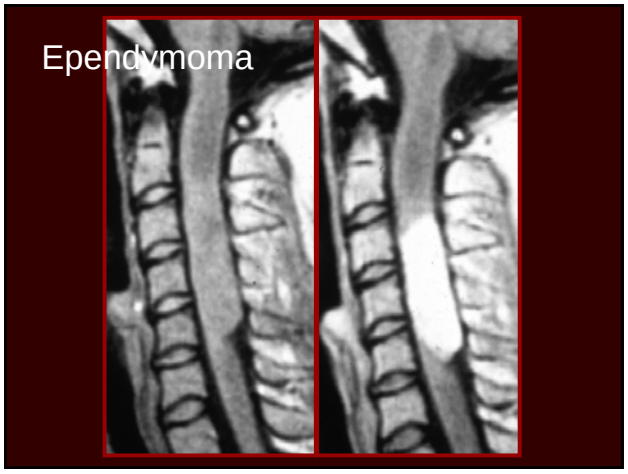
Ependymoma

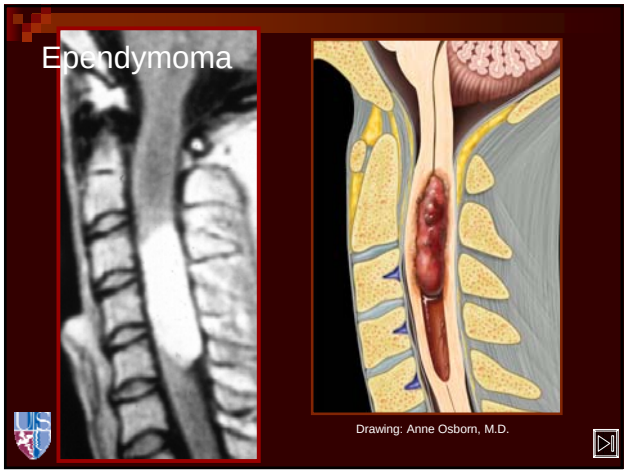
Ependymoma
Drawing: Anne Osborn, M.D.

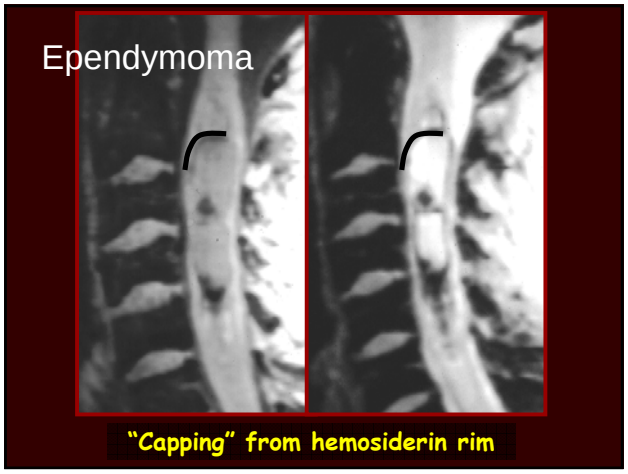
Ependymoma
"Capping" from hemosiderin rim

## CERVICAL CORD EPENDYMOMA

- Fusiform cord enlargement
- Hemorrhagic capping, seen better on T2* (GRI, SWI)

## Ependymoma

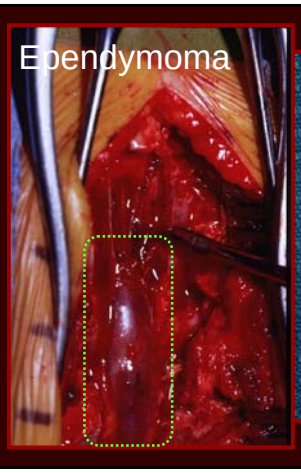

Sharply demarcted

## Ependymoma – Central Cord

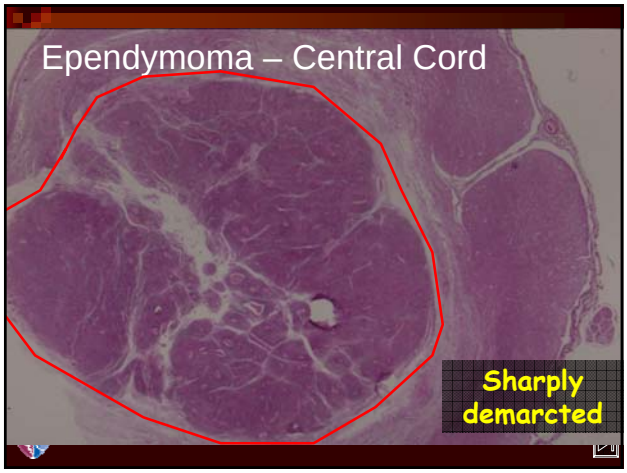

Sharply demarcted

## Ependymoma – Central Cord

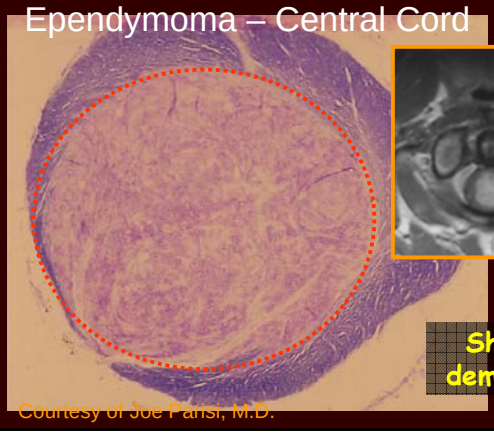

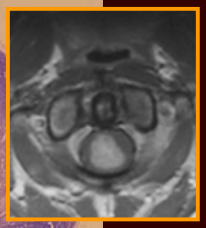

Sharply demarcted

Courtesy of Joe Parisi, M.D.

## Filum Terminale Ependymoma

- Sausage like mass, filling central canal, with marked enhancement.
- Most common location of spine ependymomas.
- Most are **Mxopapillary Ependymoma**

## Myxopapillary Ependymoma

Conus Medullaris

Sharply demarcted

## Myxopapillary Ependymoma

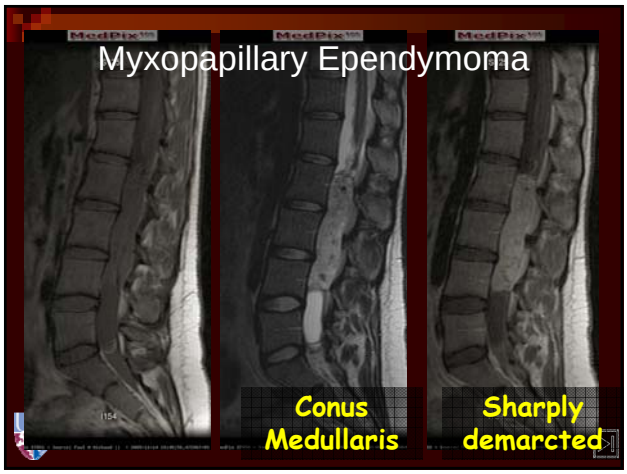


## Myxopapillary Ependymoma

## Myxopapillary Ependymoma

- 13% of spinal ependymomas
- Predilection for conus or filum
- Occasionally occur in extradural space
- Multiple lesions: 14-43%
- Lobulated soft mass often ecapsulated

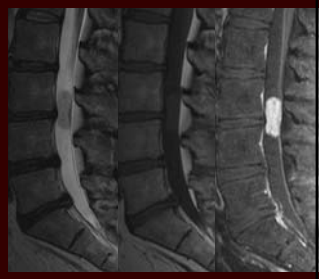

## Myxopapillary Ependymoma

## Myxopapillary Ependymoma

## Myxopapillary Ependymoma

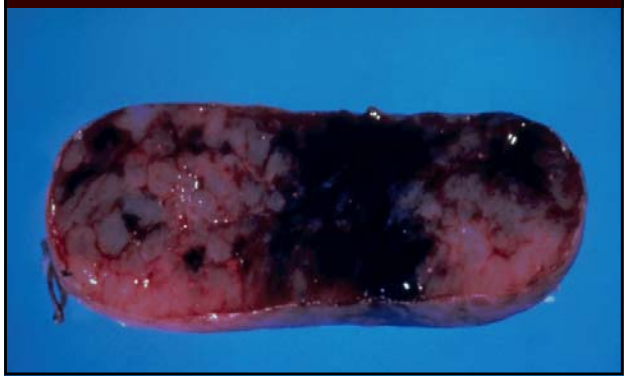

## Myxopapillary Ependymoma

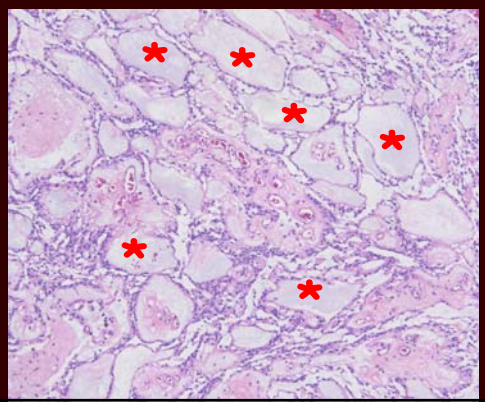

## Myxopapillary Ependymoma

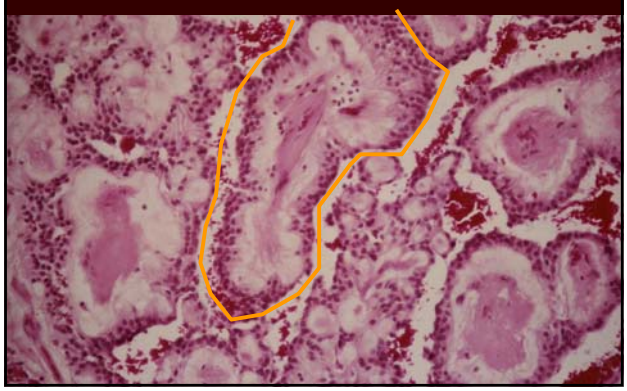

## Myxopapillary Ependymoma

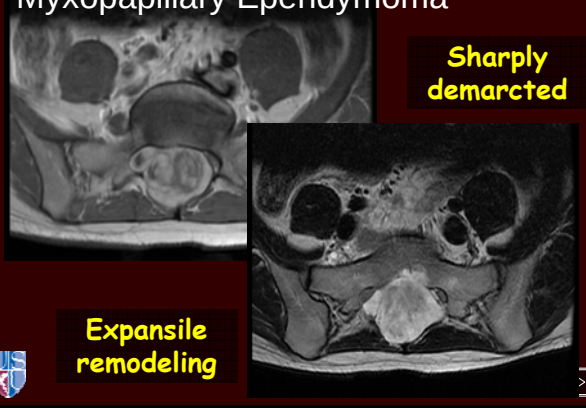


## Myxopapillary Ependymoma

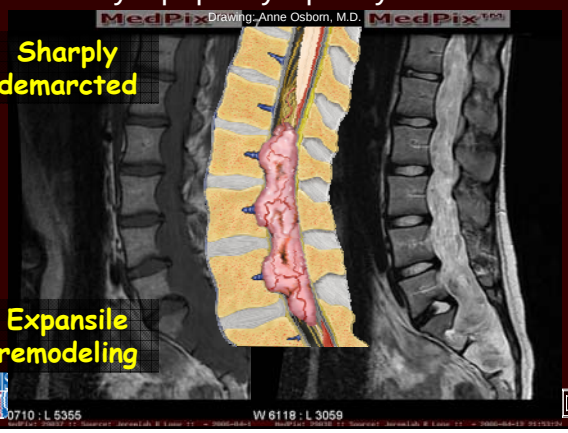


## Spine - Intradural Lesions

- Intramedullary
  - Ependymoma
  - **Astrocytoma**
  - Hemangioblastoma
  - Syringohydromyelia

## Cord Astrocytoma looks similar to Ependymoma, but …

- Patients are often younger
  - Children have pilocytic astrocytoma
- Lesions more likely to be cervical or thoracic
  - Less often lumbar or conus medullaris
- Lesions less likely to have blood, hemosiderin rare
- Enhancement poorly correlates with histology – unlike intracranial tumors

## Astrocytoma

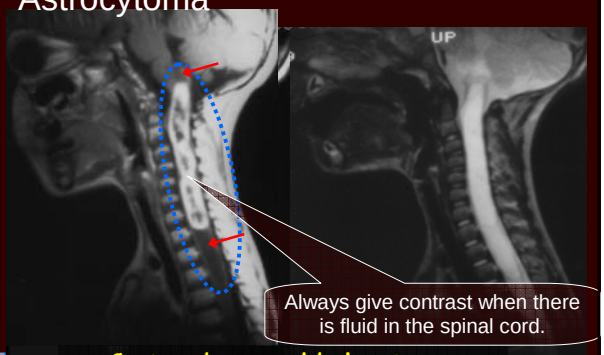


Cyst – above and below tumor

## Cord Glioma: Differential Diagnosis

| | Ependymoma | Astrocytoma |
|---|---|---|
| Age | Adult | Pediatric |
| Location | Central | Eccentric |
| Morphology | Well-circumscribed | Ill-defined |
| Hemorrhage | Common | Uncommon |
| Enhancement | Focal, intense, homogeneous | Patchy, irregular |
| Conus or filum | Yes | Atypical |

Koeller et al, RadioGraphics 2000;20:1721-1749.

## Astrocytoma

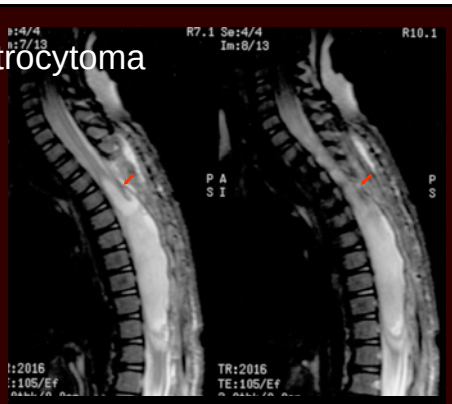

NOTE: expansile remodeling of spinal canal

## Astrocytoma

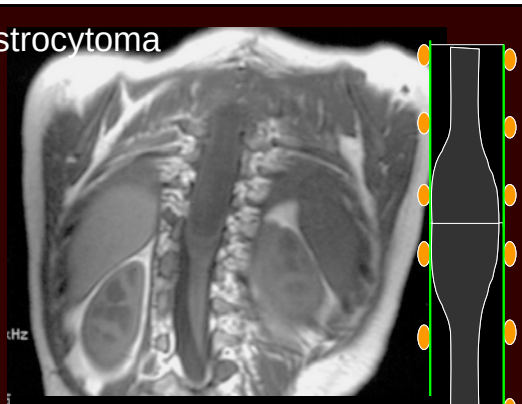

NOTE: expansile remodeling of spinal canal

## Pilocytic Astrocytoma

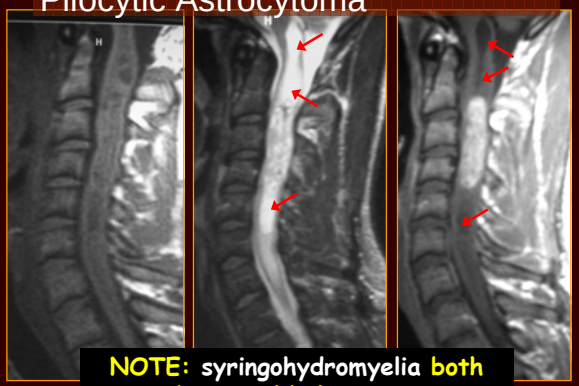

NOTE: syringohydromyelia both above and below tumor



## Astrocytoma

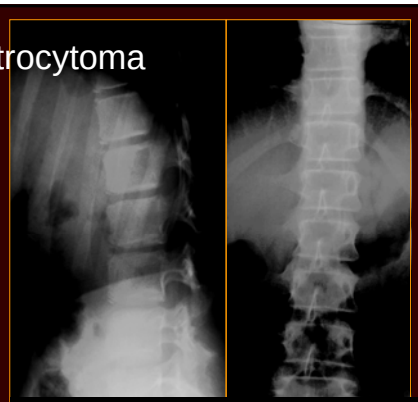

NOTE: expansile remodeling of spinal canal

## Astrocytoma

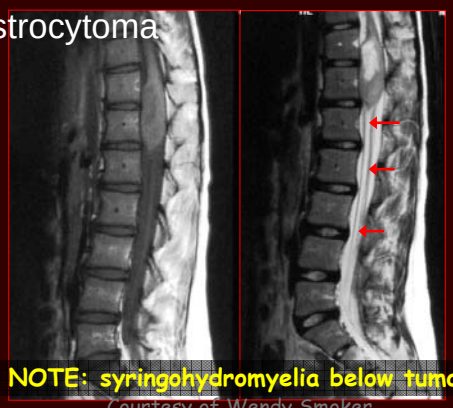


2/3

Courtesy of Wendy Smoker

## Spine - Intradural Lesions

- Intramedullary
  - Ependymoma
  - Astrocytoma
  - **Hemangioblastoma**
  - Syringohydromyelia

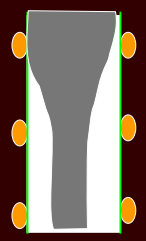

Intra-medullary

## HEMANGIOBLASTOMA

- Synonyms: H...endothelioma, Angioblastic meningioma, Lindau Tumor
- Cell of Origin: Vascular, Endothelial?
- Associations: von Hippel-Lindau (20%), (multiple in 5%, w/o VHL)
- Incidence: 1-3% of ALL Intracranial
- Age: 30-45 (peak 33/35)
- Sex: 1-2M/1F
- Location: Subpial CRBLL > Medulla > Spinal
- Treatment: Surgery, Radiation
- Prognosis: 92% at 5yrs. (small series)

## HEMANGIOBLASTOMA

- 1-15% of Cord Tumors
- 85-90% are Intramedullary
- 10-15% occur in Nerve Roots
- 50% Thoracic, 15% Cervical
- 20% Multiple
- 1/3 of pts. will have VHL
- Suggestive for Hemangioblastoma
  - cyst (rimmed by enhancement)
  - flow voids (hypervascular)
  - signs of hemorrhage

## Hemangioblastoma:

- True Neoplasm Endothelial Origin
- Hypervascular
  - capillary to sinusoidal
  - dilated feeding artery
  - dilated draining vein
  - slow flow
- Stromal Cells
  - foamy, lipid-laden

## von Hippel-Lindau: Hemangioblastoma

- Cerebellum 66%
- Retina ("angiomas") 58%
- Spinal Cord/Roots 28%
- Medulla 14%

## Hemangioblastoma and VHL:

- 1/6-1/5 of solitary cerebellar hemangioblastomas are associated w/ VHL
- Up to 1/2 of intramedullary HBL occur in VHL
- "ALL" Multiple HBL are VHL
- There was one family w/o VHL and multiple inherited HBL

## Hemangioblastoma

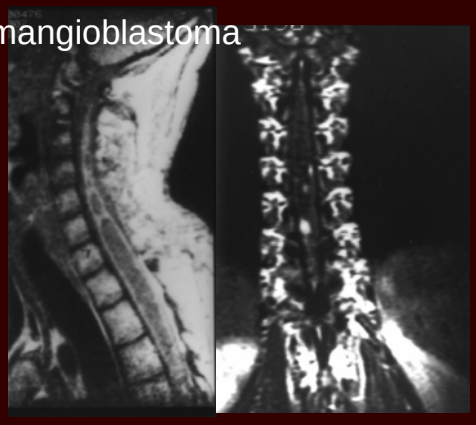

## VHL - Multiple hemangioblastomas

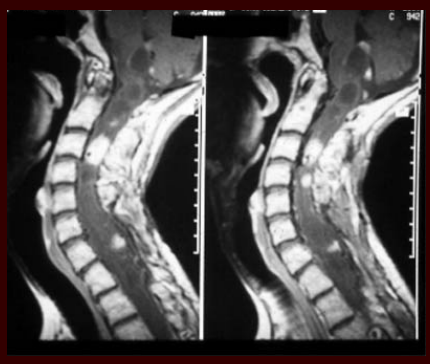

Courtesy of Greg Petermann, M.D.

## VHL - Multiple hemangioblastomas

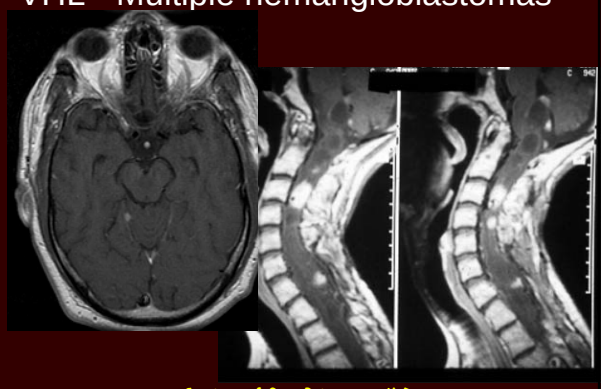

Courtesy of Greg Petermann, M.D.

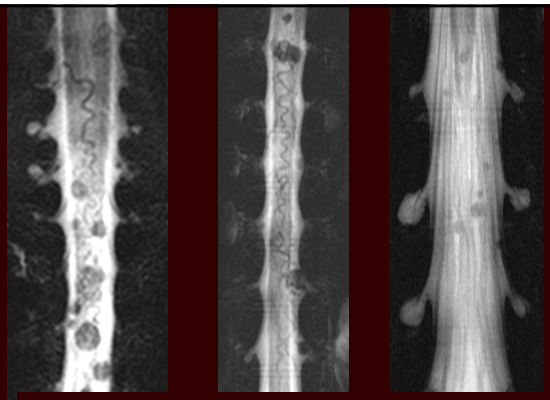

## Hemangioblastoma

## DDx of EXPANDED CORD

- Primary & Secondary Neoplasms
- Myelitis, Abscess
- Granuloma
- **Acute MS**
- Syringohydromyelia (primary/secondary)
- Vascular - Infarct, Edema
- Trauma - Hematoma, Contusion, Edema

## Acute Multiple Sclerosis

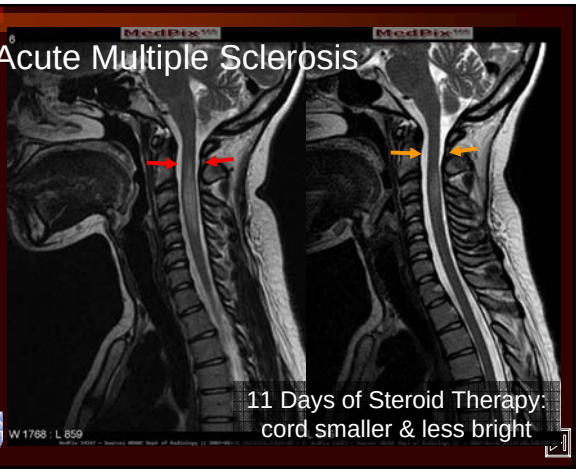


11 Days of Steroid Therapy:
cord smaller & less bright

## Cavernous Malformation

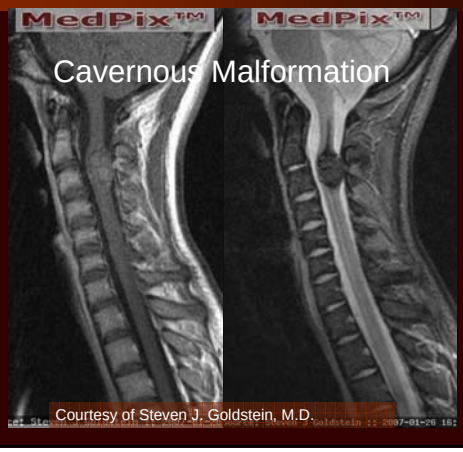


Courtesy of Steven J. Goldstein, M.D.

## Cavernous Malformation

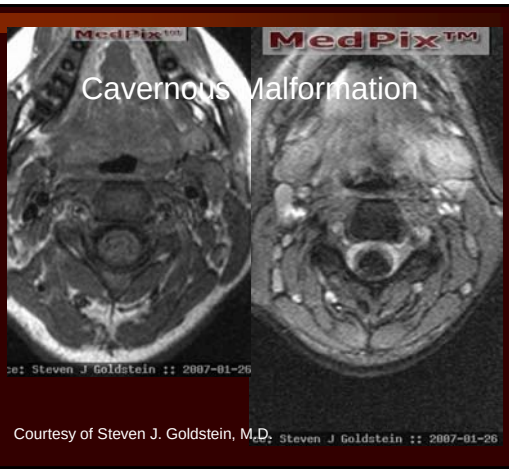


Courtesy of Steven J. Goldstein, M.D.

## Cavernous Malformation

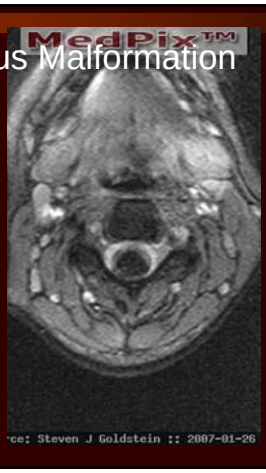


## Spine - Intradural Lesions

- Intramedullary
  - Ependymoma
  - Astrocytoma
  - Hemangioblastoma
  - Syringohydromyelia

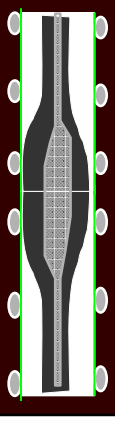

## SYRINGOHYDROMYELIA

- GR. "SYRINX' a pipe or straw (hollow reed)
  - A Fluid-Filled Cavity within the Cord
  - usually central
- **Hydromyelia = Ependymal-lined**
  - An Enlarged Central Canal
  - often the Ependyma is destroyed
- Loss of Pain & Temperature Fibers
  - Quien es mas macho?

## Loss or Pain, Temp, Position

**Historical Note**

First Recorded Case of Syringohydromyelia:
Gaius Mucius Scaevola, Legendary Roman Hero

When Lars Porsena, an Etruscan chieftain, besieged Rome in 509 B.C., Gaius Mucius offered to kill him. Captured and sentenced to be burned alive, Gaius Mucius thrust his right hand into an altar fire and held it there without flinching in order to show his indifference to physical pain. Impressed, Porsena freed Gaius Mucius and made peace with Rome.

## Syringo-Hydromyelia, Gliosis

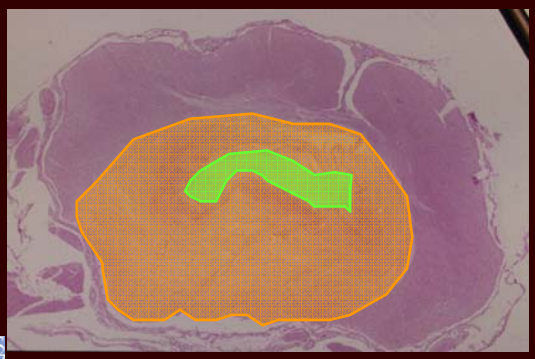

## SYRINGOHYDROMYELIA

- Idiopathic (Congenital?)
  - do not enhance, smooth
  - Associated w/Chiari Malformations
    - Chiari 1 (30%)
    - Chiari 2 (60%) (Myelomeningocele)
  - Associated w/Neoplasms
- Differential Diagnosis – Fluid secretion
  - Pilocytic Astrocytoma
  - Hemangioblastoma

## Syringohydromyelia

## Syringohydromyelia

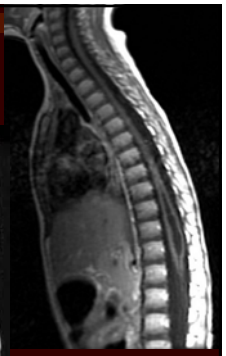

## Syringohydromyelia

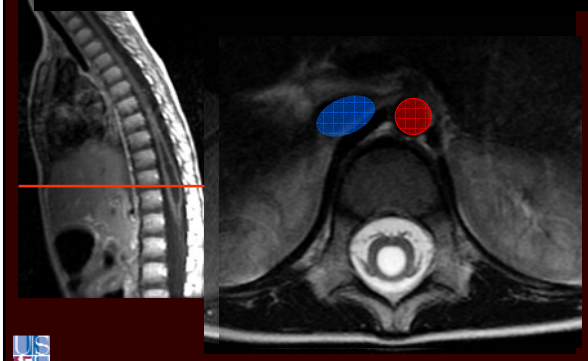

## Syringohydromyelia

- Always look for a “cause”
- Always give contrast
  - Fluid Secreting Tumor
  - Altered CSF flow from tumor

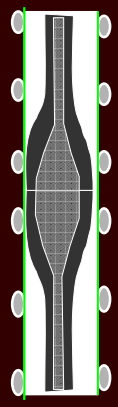

## Hydromyelia

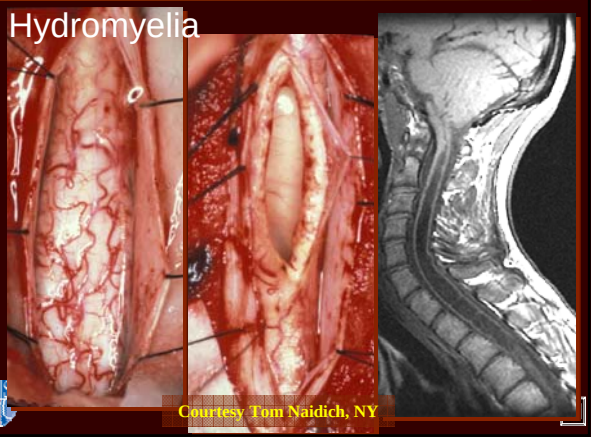


## Summary: Expanded Spinal Cord

- Primary & Secondary Neoplasms
- Myelitis, Abscess
- Granuloma
- Acute MS
- Syringohydromyelia (primary/secondary)
- Vascular - Infarct, Edema
- Trauma - Hematoma, Contusion, Edema

## Localization of Spinal Masses

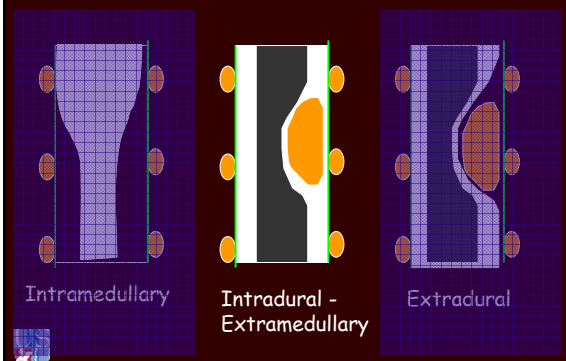

## Spine - Intradural Lesions

- Intramedullary
  - Ependymoma
  - Astrocytoma
  - Hemangioblastoma
- Extramedullary
  - **Meningioma**
  - Schwannoma
  - Epidermoid
  - Paraganglioma
  - Metastasis

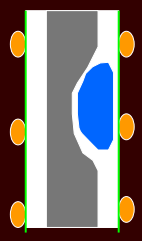

Extra-medullary

## Meningioma

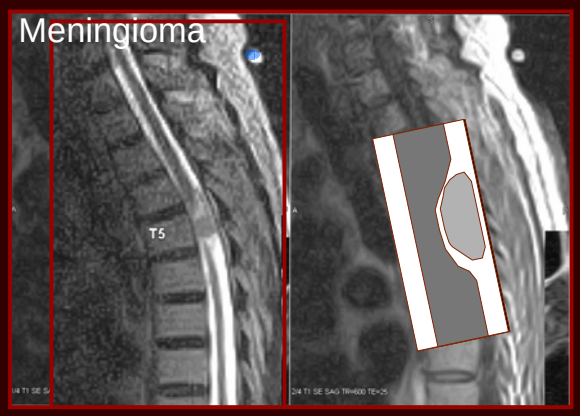


## Meningioma

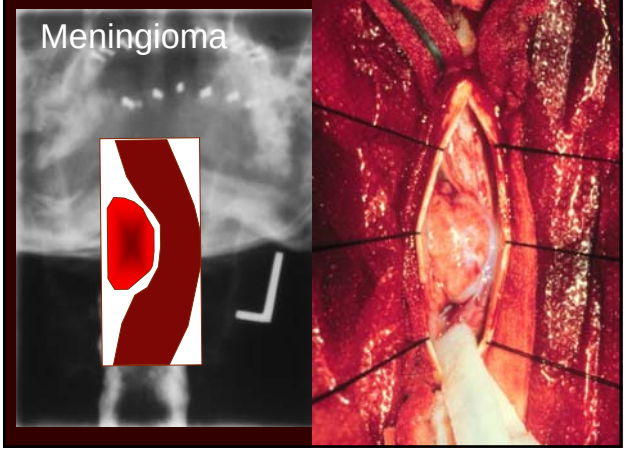

## Meningioma

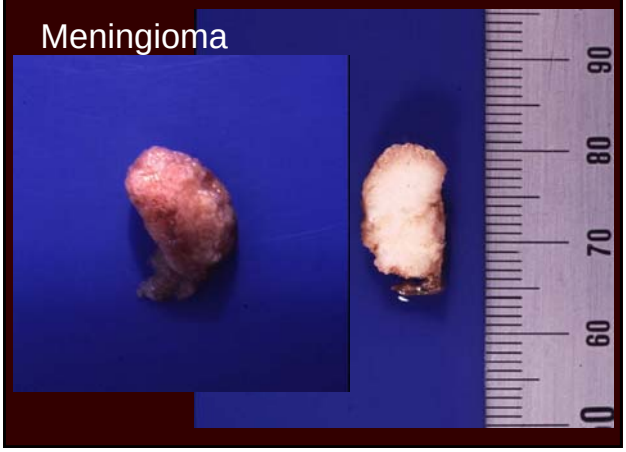


## Psammomatous Meningioma

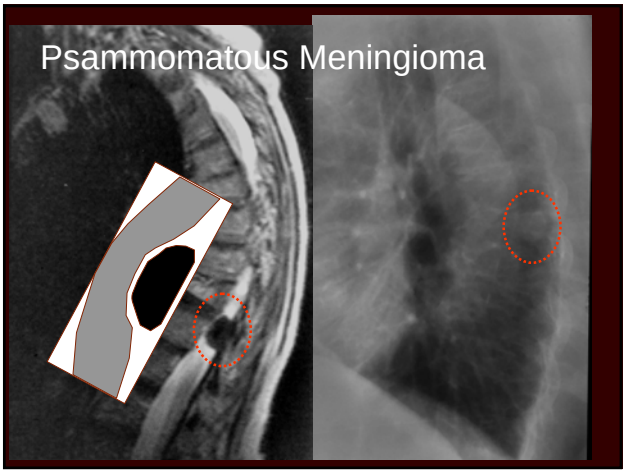

## Solitary Fibrous Tumor

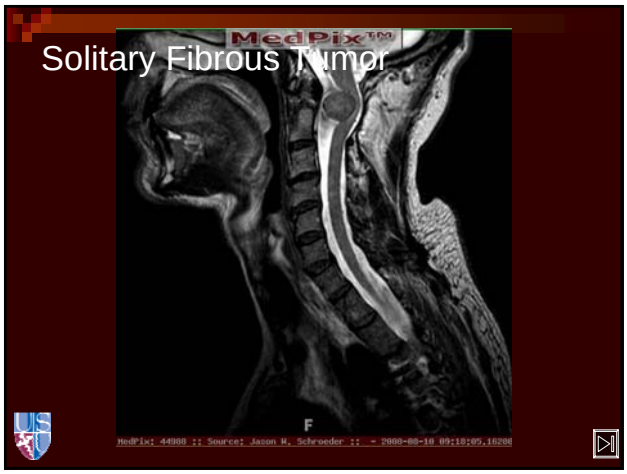


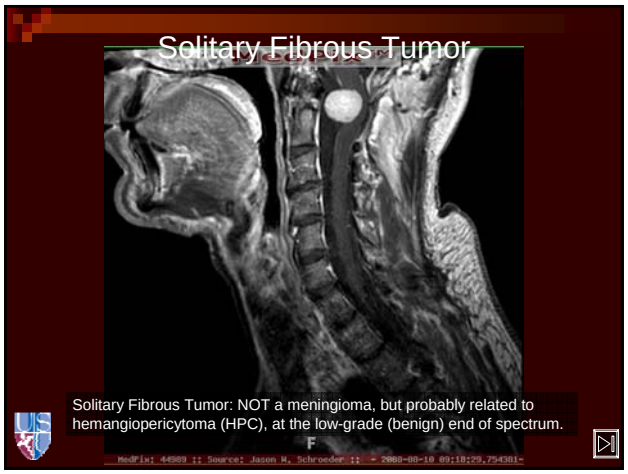


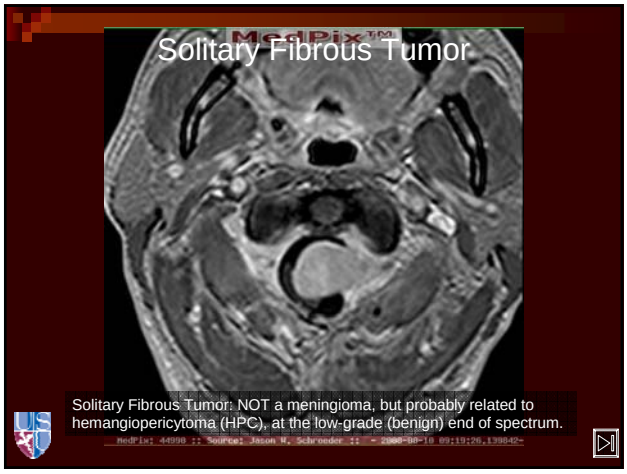


## Spine - Intradural Lesions

- Intramedullary
  - Ependymoma
  - Astrocytoma
  - Hemangioblastoma
- Extramedullary
  - Meningioma
  - **Schwannoma**
  - Epidermoid
  - Paraganglioma
  - Metastasis

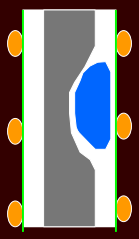

Extra-medullary

## Schwannoma

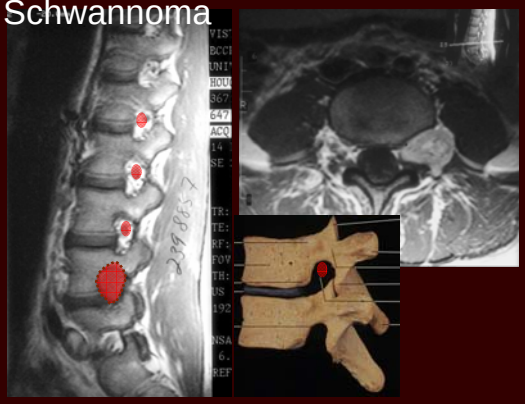

## Schwannoma

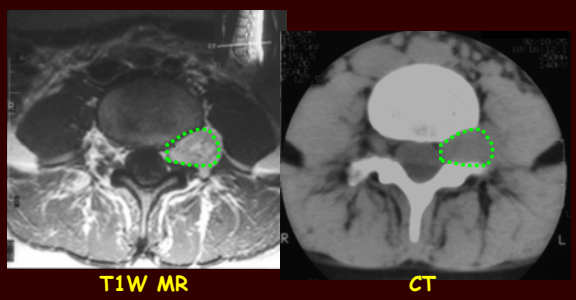


## Schwannoma

## NF-2

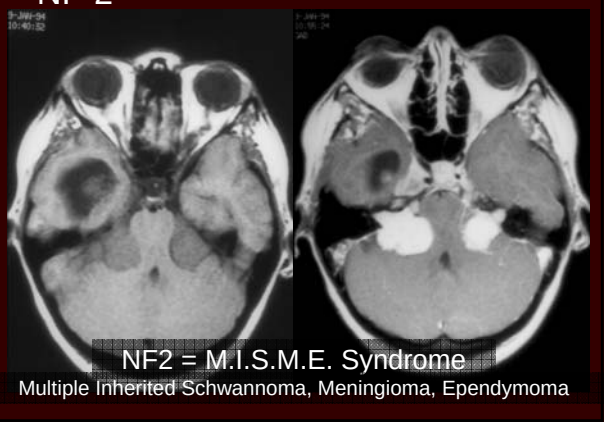


## Spine - Intradural Lesions

- Intramedullary
  - Ependymoma
  - Astrocytoma
  - Hemangioblastoma
- Extramedullary
  - Meningioma
  - Schwannoma/**Neurofibroma**
  - Epidermoid
  - Paraganglioma
  - Metastasis

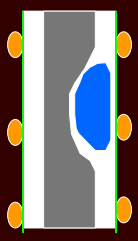

Extra-medullary

## NF1: Multiple Neurofibromas

## NF1: Multiple Neurofibromas

Courtesy of Greg Petermann, M.D.

## Sporadic Schwannoma vs. Multiple Neurofibromas in NF-1

## Spine - Intradural Lesions

- Intramedullary
  - Ependymoma
  - Astrocytoma
  - Hemangioblastoma
- Extramedullary
  - Meningioma
  - Schwannoma
  - **Epidermoid**
  - Paraganglioma
  - Metastasis

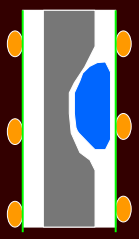

Extra-medullary

## Epidermoid

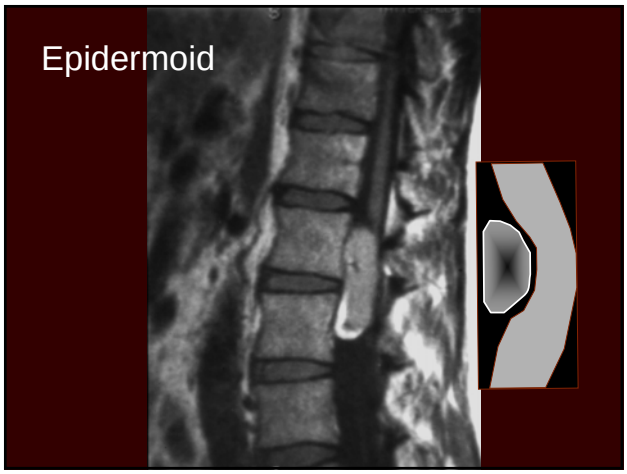


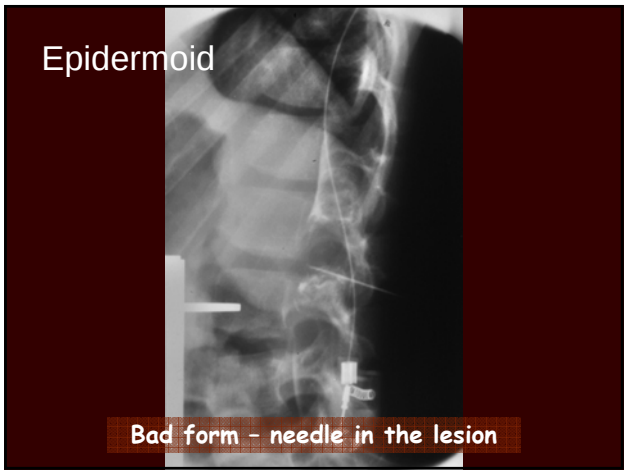


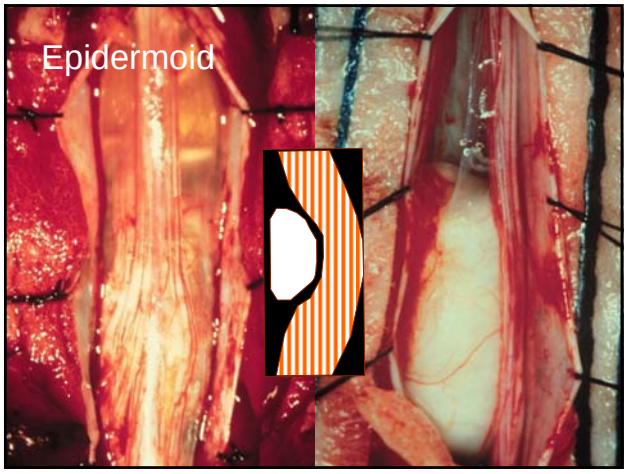

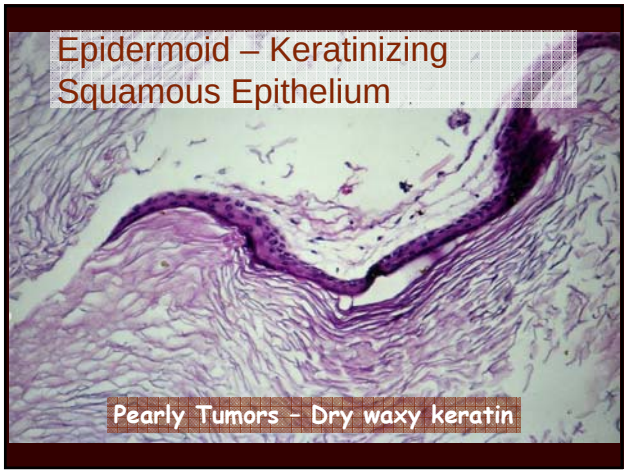


## Spine - Intradural Lesions

- Intramedullary
  - Ependymoma
  - Astrocytoma
  - Hemangioblastoma
- Extramedullary
  - Meningioma
  - Schwannoma
  - Epidermoid, **Lipoma**
  - Paraganglioma
  - Metastasis

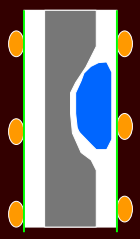

Extra-medullary

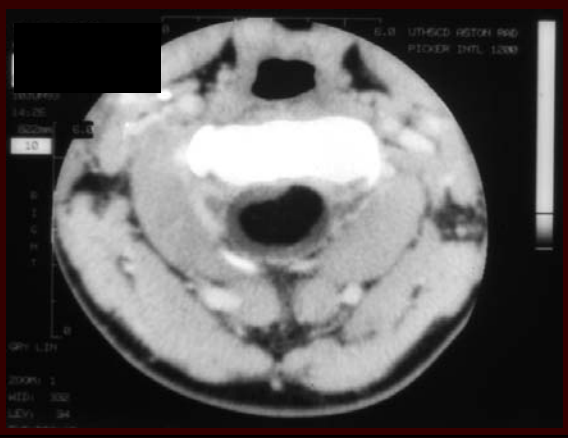

## Lipoma

## Spine - Intradural Lesions

- Intramedullary
  - Ependymoma
  - Astrocytoma
  - Hemangioblastoma
- Extramedullary
  - Meningioma
  - Schwannoma
  - Epidermoid
  - **Paraganglioma**
  - Metastasis

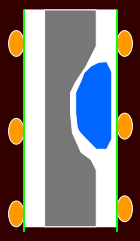

Extra-medullary

## HNP … and a Cauda Paraganglioma

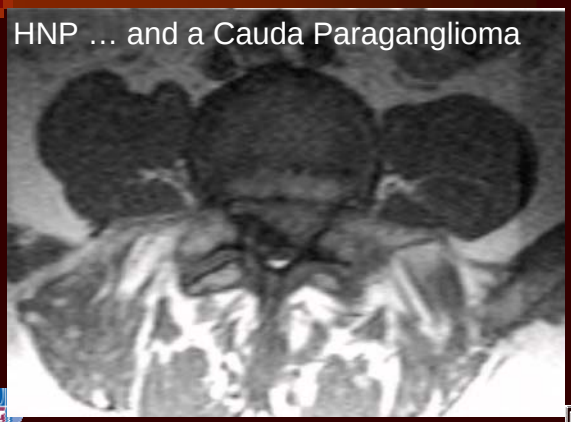

## HNP … and a Cauda Paraganglioma

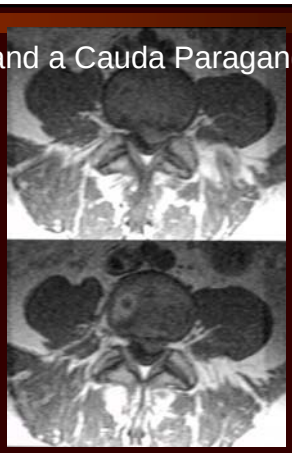

## HNP … and a Cauda Paraganglioma

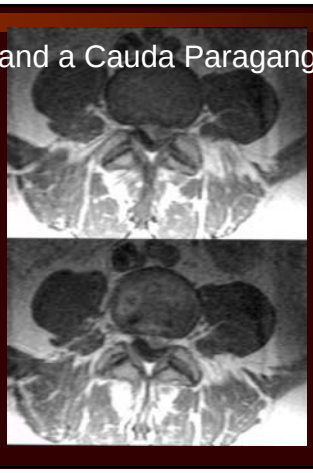

## Lumbar Disk Herniation …

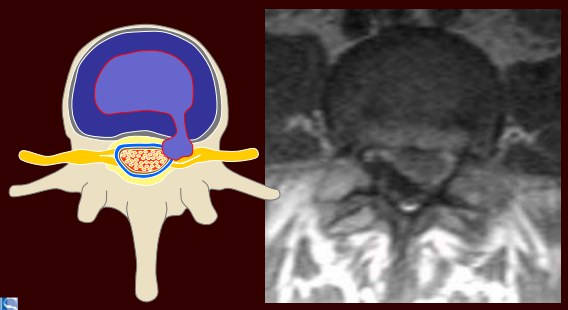

## HNP … and a Cauda Paraganglioma

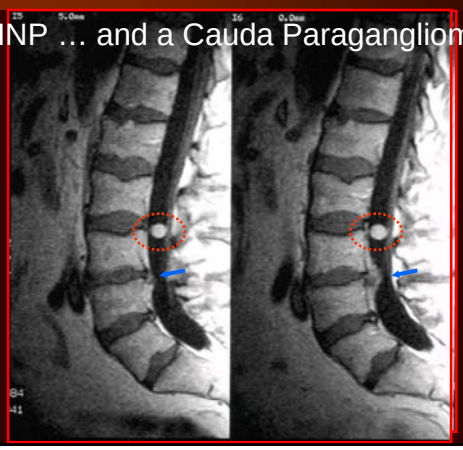

## Paraganglioma

- Non-chromaffin paraganglioma
- Conus medullaris/filum terminale
- Often hypervascular
  - May have blood products
- Small round mass

## Extramedullary-Extradural

- HNP – Herniated Nucleus Pulposis
- Synovial Cyst (apophyseal joint)
- Epidural
  - Abscess, Hematoma
  - Lipomatosis
  - Lymphoma, Metastasis
- Vertebral body neoplasms
  - Metastasis
  - Giant cell tumor, Aneurysmal Bone Cyst
  - Hemangioma, Extramedullary Hematopoeisis

## Spine - Intradural Lesions

- Intramedullary
  - Ependymoma
  - Astrocytoma
  - Hemangioblastoma
- Extramedullary
  - Meningioma
  - Schwannoma
  - Epidermoid
  - Paraganglioma
  - **Metastasis**

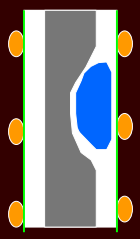

Extra-medullary

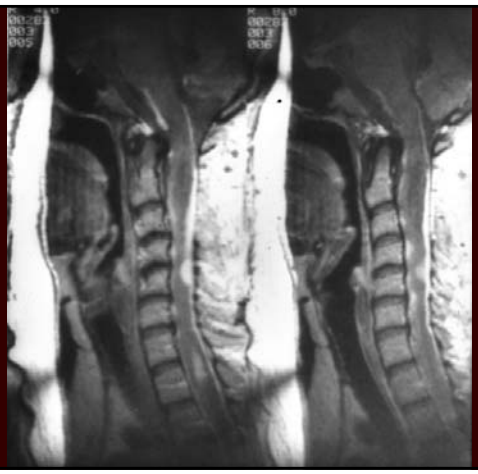

## CSF Metastases

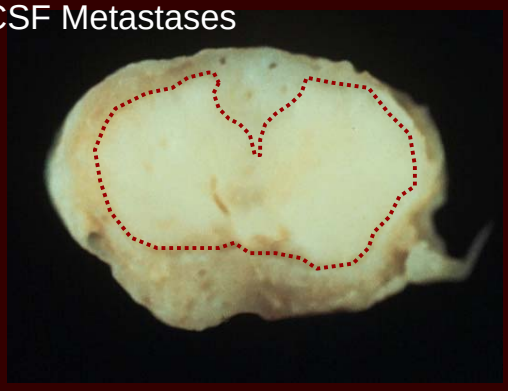

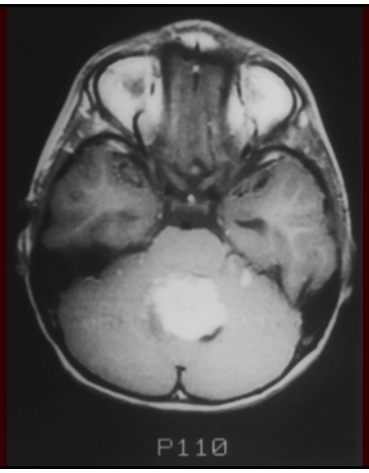


## Medulloblastoma Dissemination

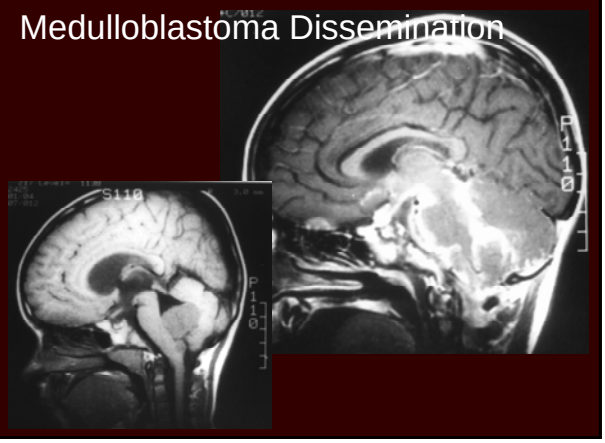


**“Zuckerguss”**
**or**
**Sugar Icing**
**(CSF dissemination)**

## CSF DISSEMINAITON

- **Neuroectodermal:**
  **PNET (medulloblastoma)**
  **GBM (reaches ventricle or pia)**
  **Ependymoma**
  **Oligodendroglioma (micro curiosity - no Sx)**
  **CPP and CPC**
- **Non-glial:**
  **Germinoma**
  **Lymphoma (usually secondary)**
  **Leukemia**
  **Carcinomatous Meningitis**

CSF Spread - Zuckerguss

CSF Spread - Zuckerguss

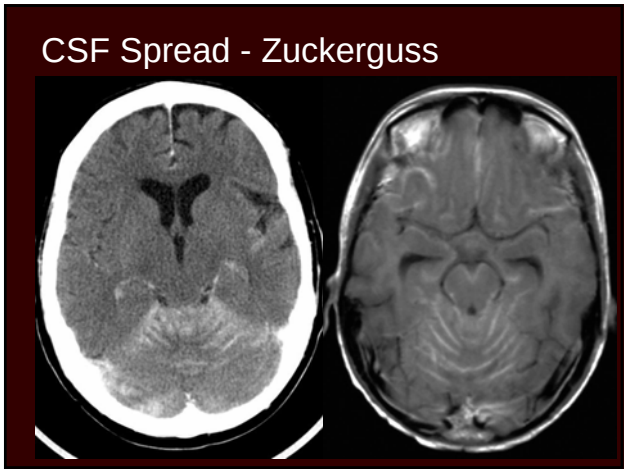
CSF Spread - Zuckerguss

MedPix™
Metastatic Lung AdenoCa

MedPix™
Metastatic Lung AdenoCa

MedPix™
Metastatic Lung AdenoCa

Metastatic Lung AdenoCa
MedPix™
1 :: Source: Steven J Goldstein :: -

Metastatic Lung AdenoCa
MedPix™
42 :: Source: Steven J Goldstein :: -

Metastatic Lung AdenoCa
MedPix™
43 :: Source: Steven J Goldstein :: -

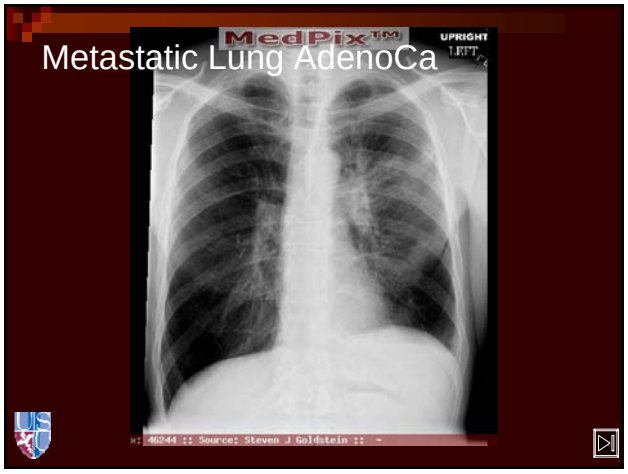
Metastatic Lung AdenoCa
MedPix™
UPRIGHT
46244 :: Source: Steven J Goldstein :: -

Metastatic Lung AdenoCa
MedPix™
46245 :: Source: Steven J Goldstein :: -

Granulocytic Sarcoma
MedPix™
46425 :: Source: Steven J Goldstein :: -

MedPix™
422 :: Source: Steven J Goldstein :: -

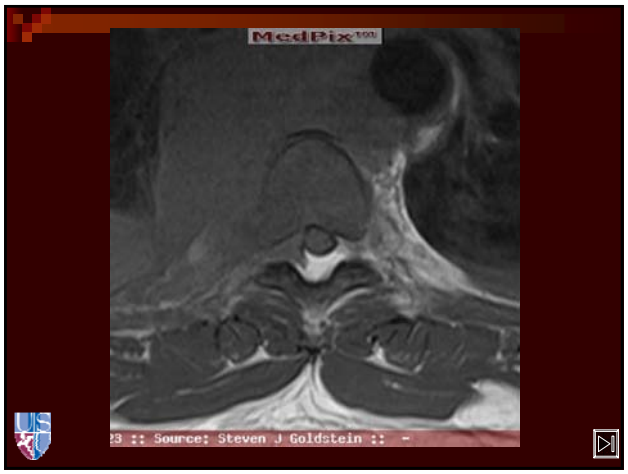
MedPix™
23 :: Source: Steven J Goldstein :: -

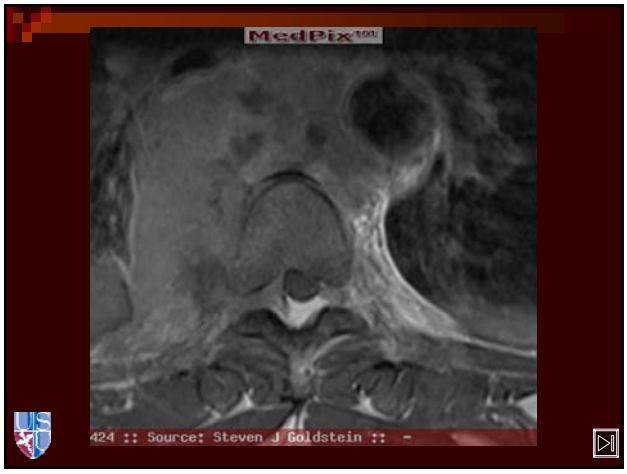
MedPix™
424 :: Source: Steven J Goldstein :: -

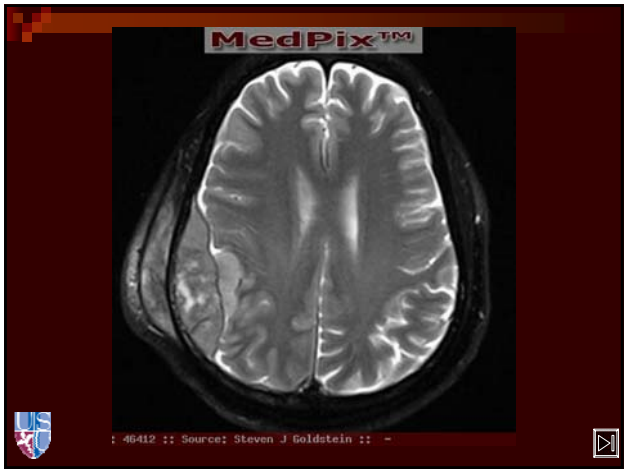
MedPix™
: 46412 :: Source: Steven J Goldstein :: -

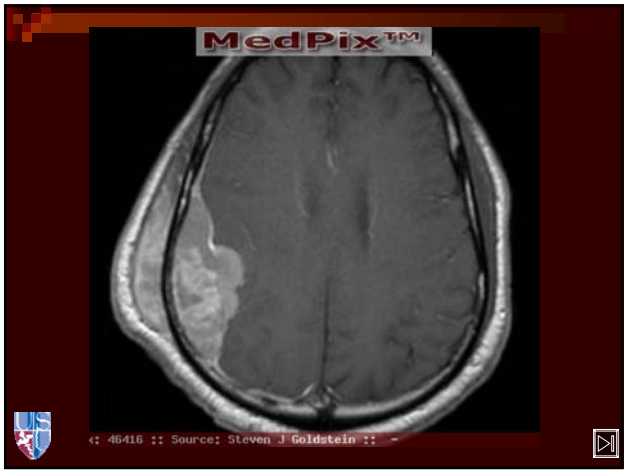
MedPix™
: 46416 :: Source: Steven J Goldstein :: -

Summary

## Localization of Spinal Masses

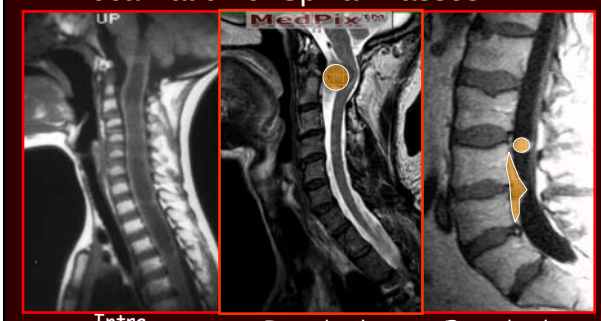


Intra-medullary | Intradural Extra-medullary | Extradural

## Thank You!

Go Raimh Maith Agat

Muito Obrigado

ΕΥΧΑΡΙΣΤΩ !

Mahalo !

Dank u wel !

Merci Beaucoup

Danke Schön !

Mil Gracias