RADIOGRAPHIC ANATOMY: Back and Upper Extremity

James G. Smirniotopoulos, M.D.
Uniformed Services University
Bethesda, MD

Educational Goals

- Understand Spine and UE Radiology
- Understand Basic Radiologic Signs:
  - Size, Shape, and Alignment
- Understand Principles of Functional Anatomy
  - Apophyses, epiphyses
  - Protuberances and ridges

- **Don't Memorize -> Understand**

BASIC UNITS

- Back & UE
- Chest
- Abdomen
  - GI and Upper Abdomen
  - GU and Lower Abdomen
- Pelvis and LE

Spine / Back

- CERVICAL (NECK) 7
- THORACIC (CHEST) 12
- LUMBAR (ABD) 5
- SACRUM 5
- COCCYX 4

Spine / Back

- Cervical Lordosis - (
- Thoracic Kyphosis -)
- Lumbar Lordosis - (

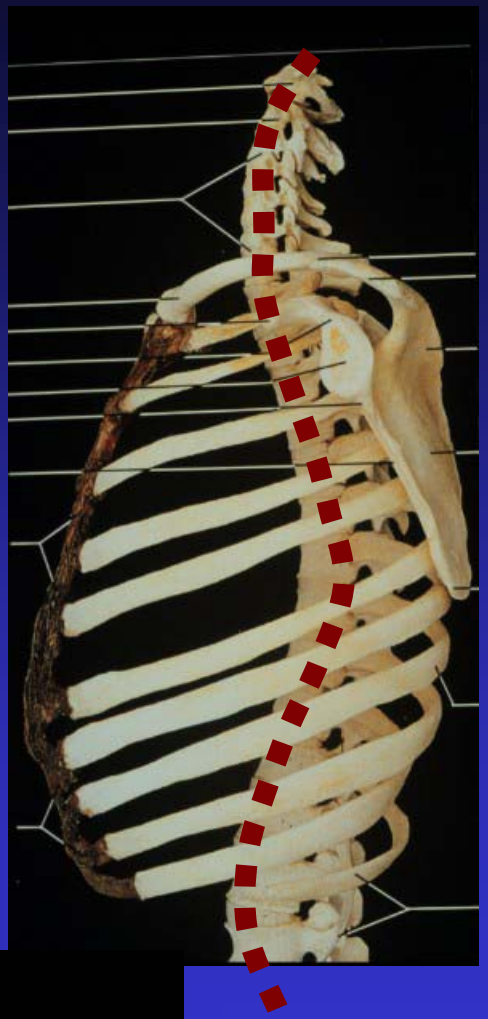

Note: Standard Image Display

- Patient is facing LEFT side of image

Vertebrae - Size, Shape, No.

- Cervical (7)
- Thoracic (12)
- Lumbar (5)
- Sacral (5)
- Coccygeal (4)

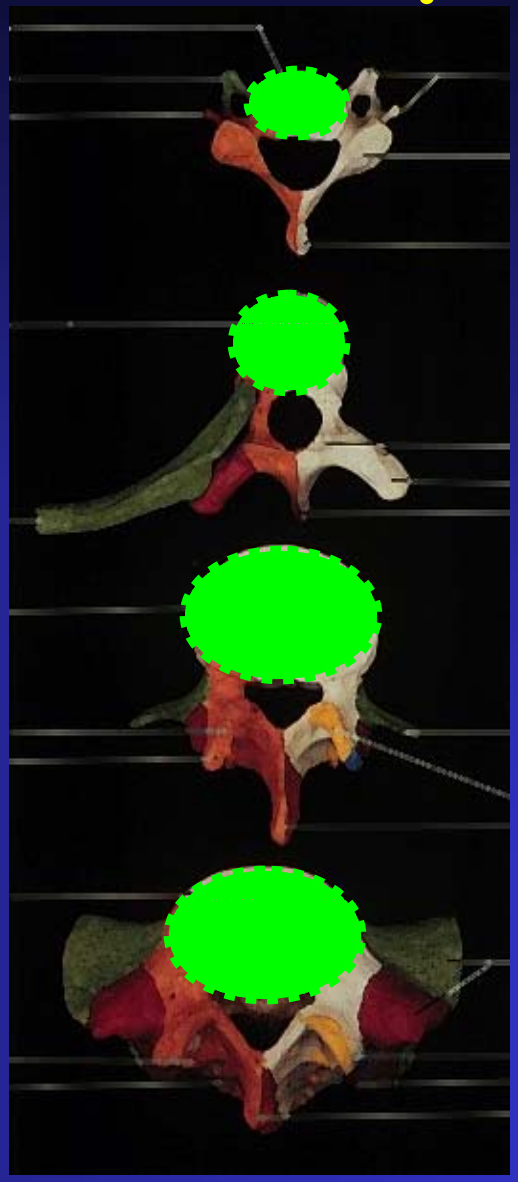

Anatomy in Alaska

Whittier, Alaska

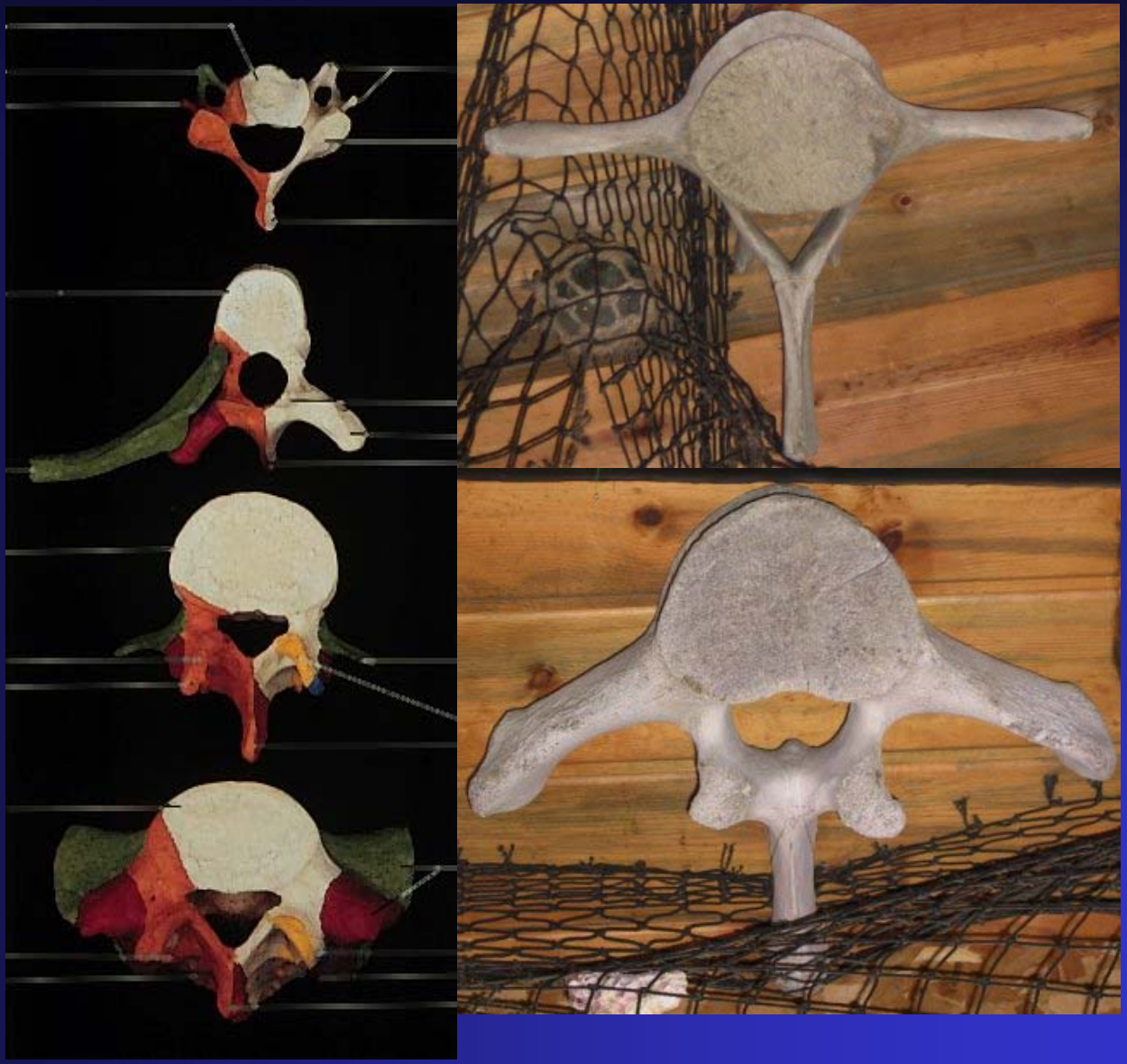

Take Two Steaks …

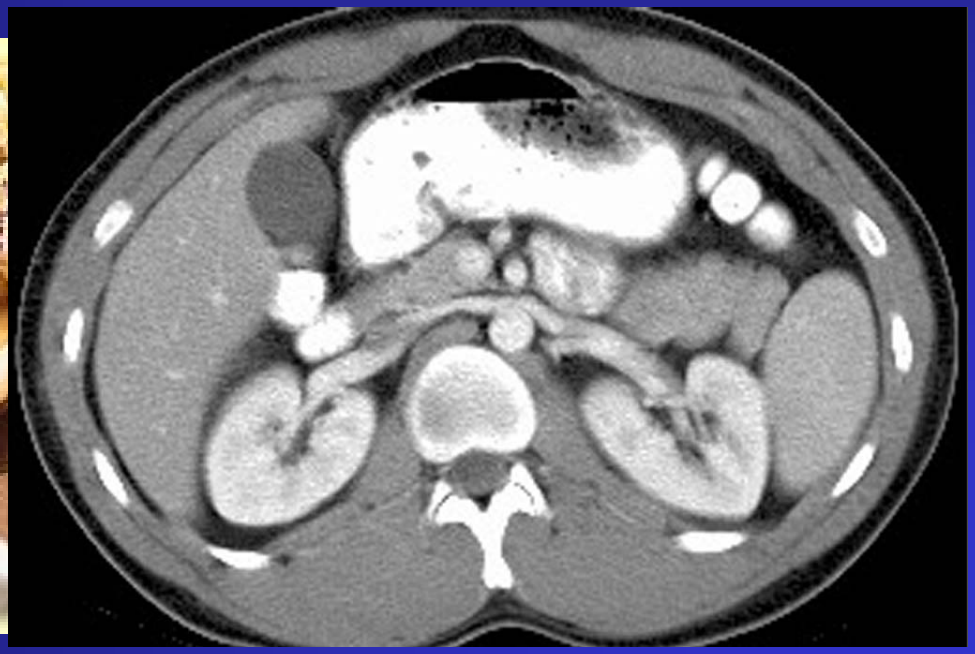

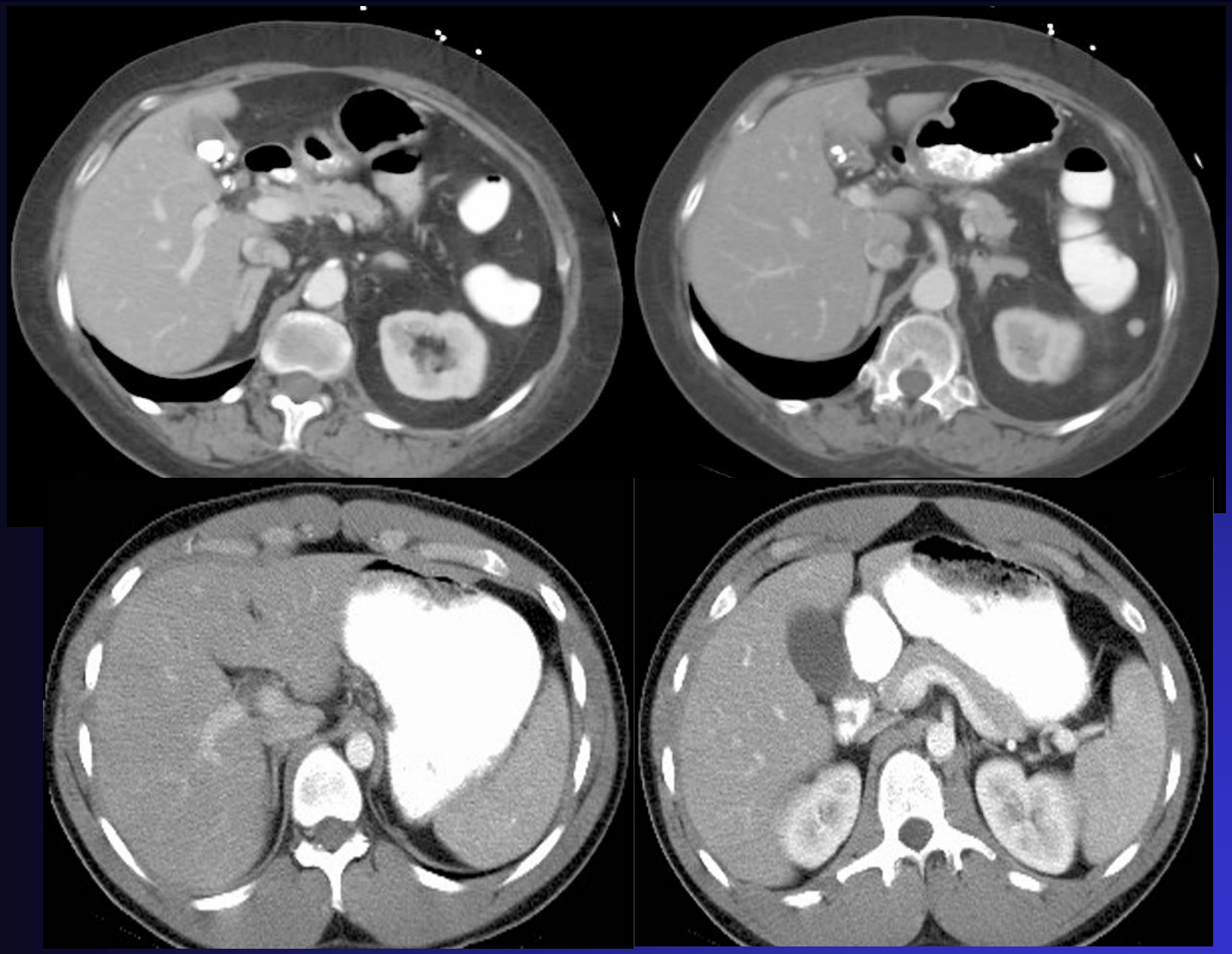

Spine / Back

- Radiographic Studies
  - Plain Film
  - MR Plain/IV Contrast
  - CT Plain/IV Contrast
  - CT / Myelography

Spine / Back

- Vertebrae
  - Body (Centrum) (1)
  - Pedicles (2)
  - Transverse Process (2)
  - Articular Process (4)
  - Lamina (2)
  - Spinous Process (1)

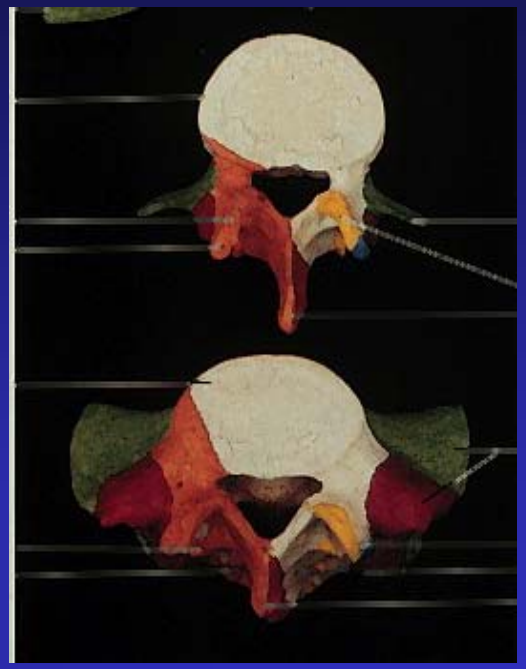

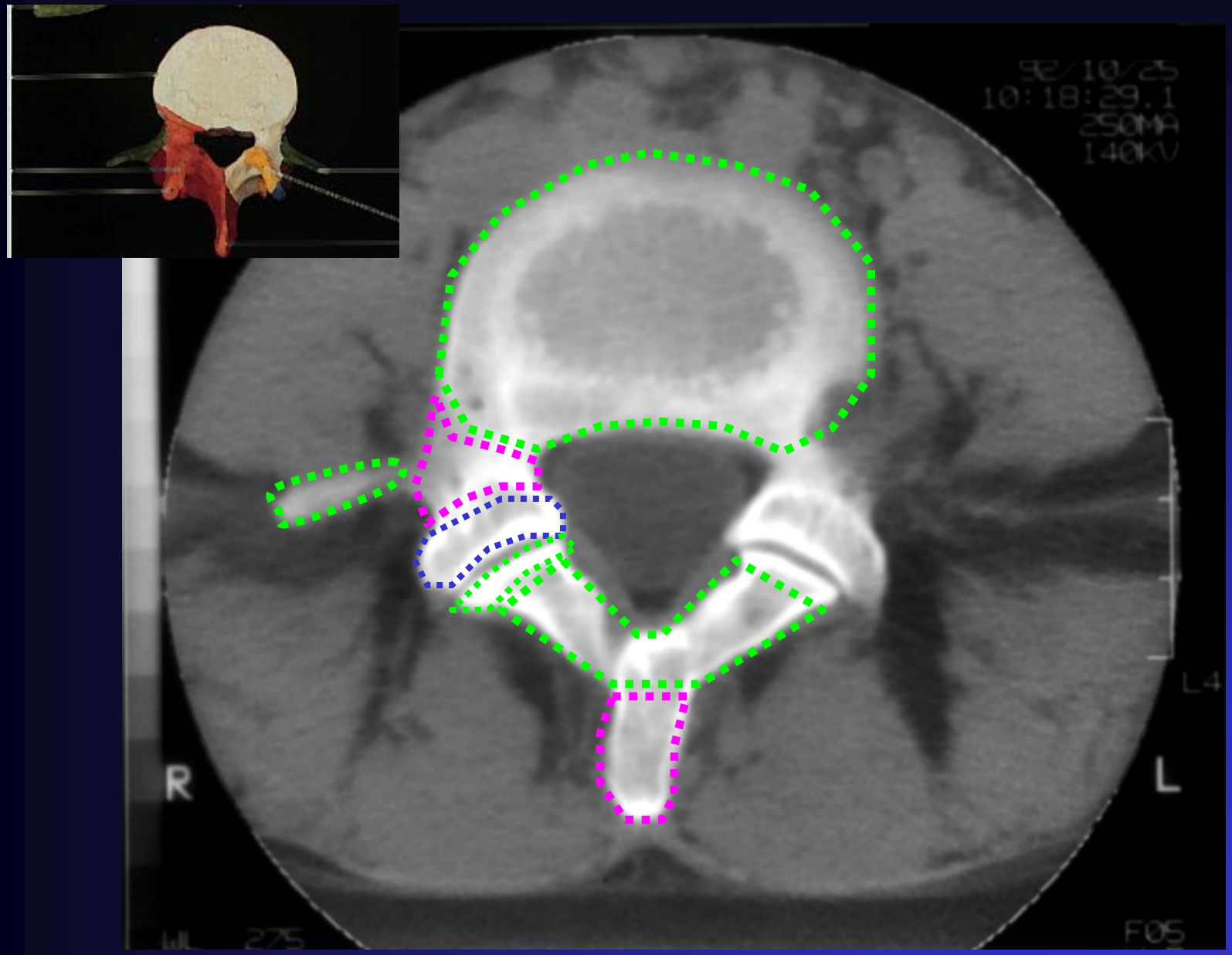
92/10/25
10:18:29.1
250MA
140KV
L4
R
L
WL 275
F05

Spine / Back

IN BETWEEN Vertebrae

- Neural Foramen (2)
  (Intervertebral F.)
- Intervertebral Disk
  - Annulus (Ring) Fibrosis
    - fibrous connective tissues
  - Nucleus (Center) Pulposis
    - jelly-like cushion (notochord)

Vertebra - Lat.

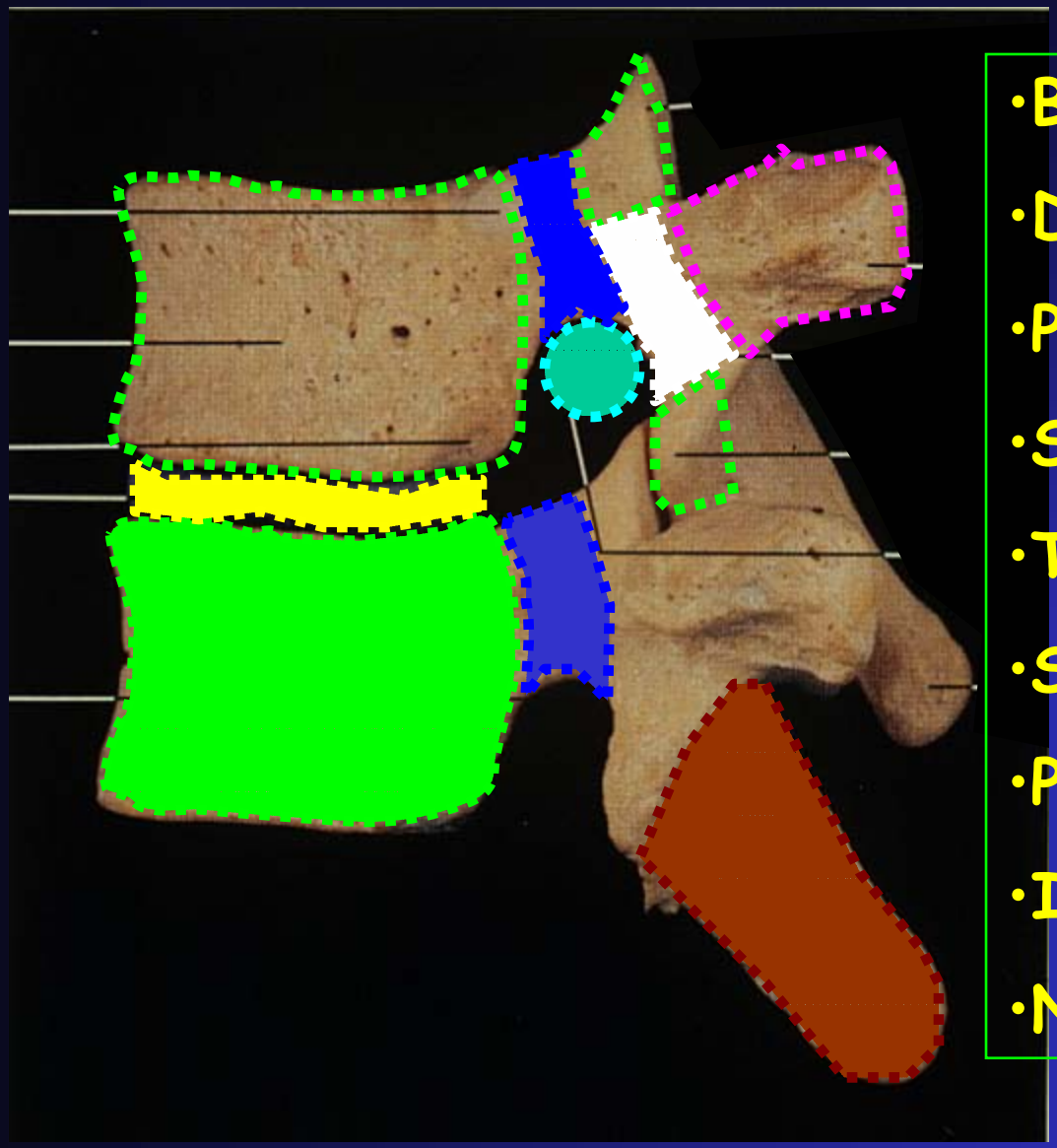

- Body
- Disc
- Pedicle
- Spinous process
- Transverse process
- Sup. Facet
- Pars inter articularis
- Inf. Facet
- Neural Foramen

Radiology - http://rad.usuhs.mil

Oblique Lumbar Spine

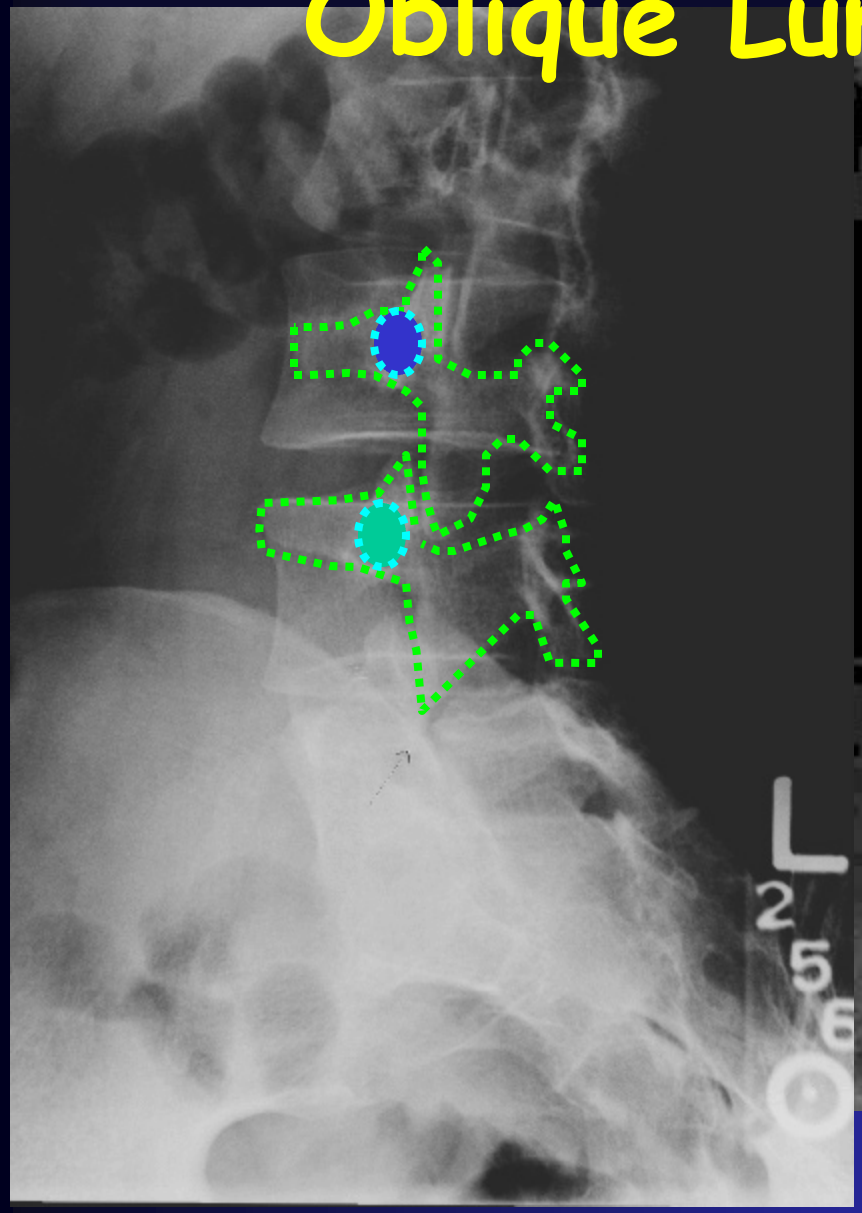

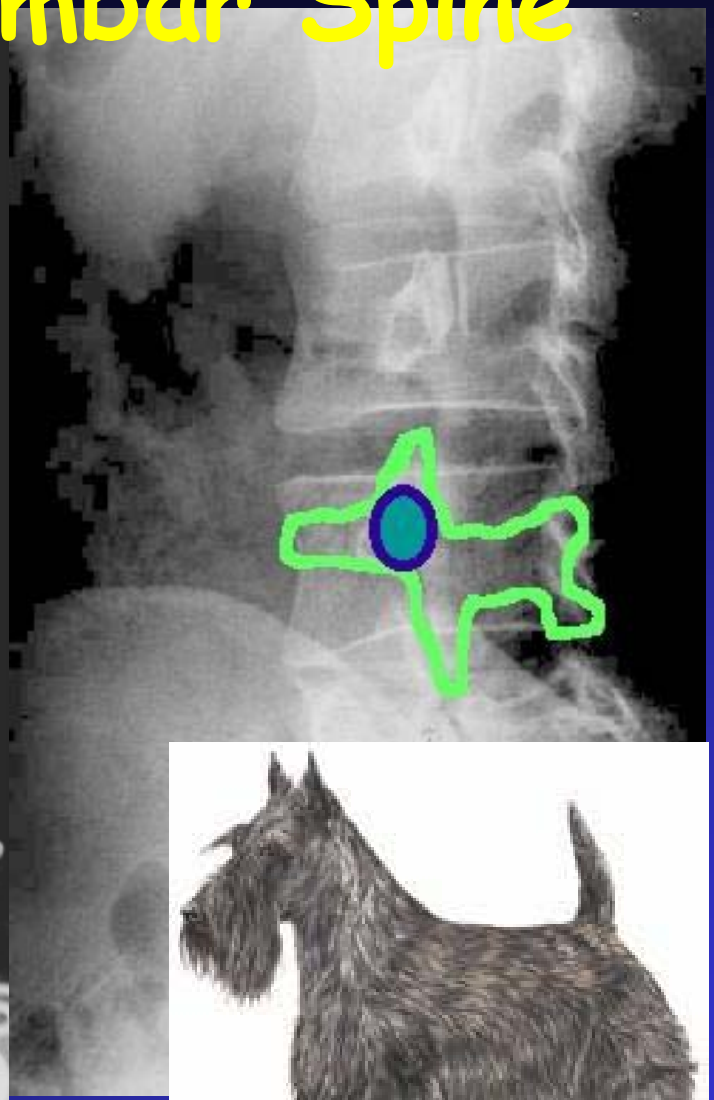

BASIC RADIOLOGIC SIGNS

Size

Shape

Number

Position and Alignment

Morphology

Density/Intensity/Echogenicity

Architecture/Texture

Function

What Study is Best?

- ER Screen
  - Plain X-ray
  - CT
- Soft tissue Joint
  - MR
- Spinal Cord and Brain
  - CT
  - MR

Cx Spine - Frontal (AP) and Lat

Cx Alignment - Lateral

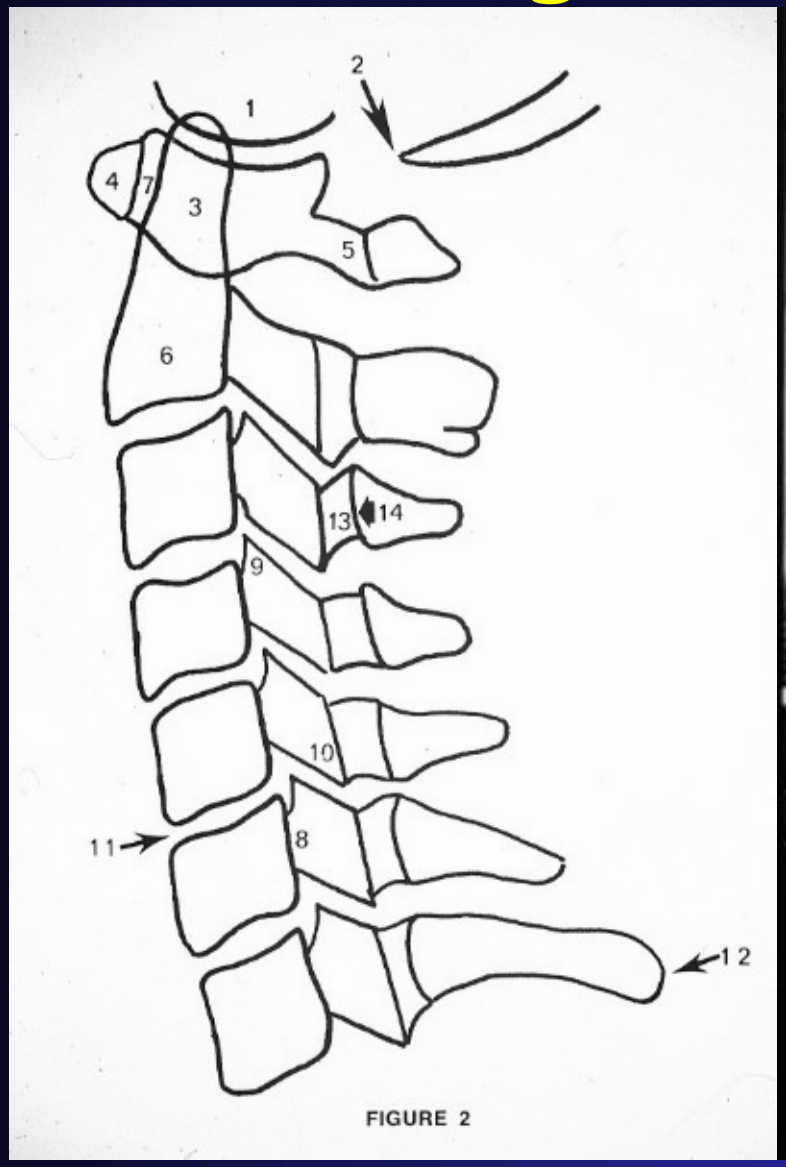

FIGURE 2

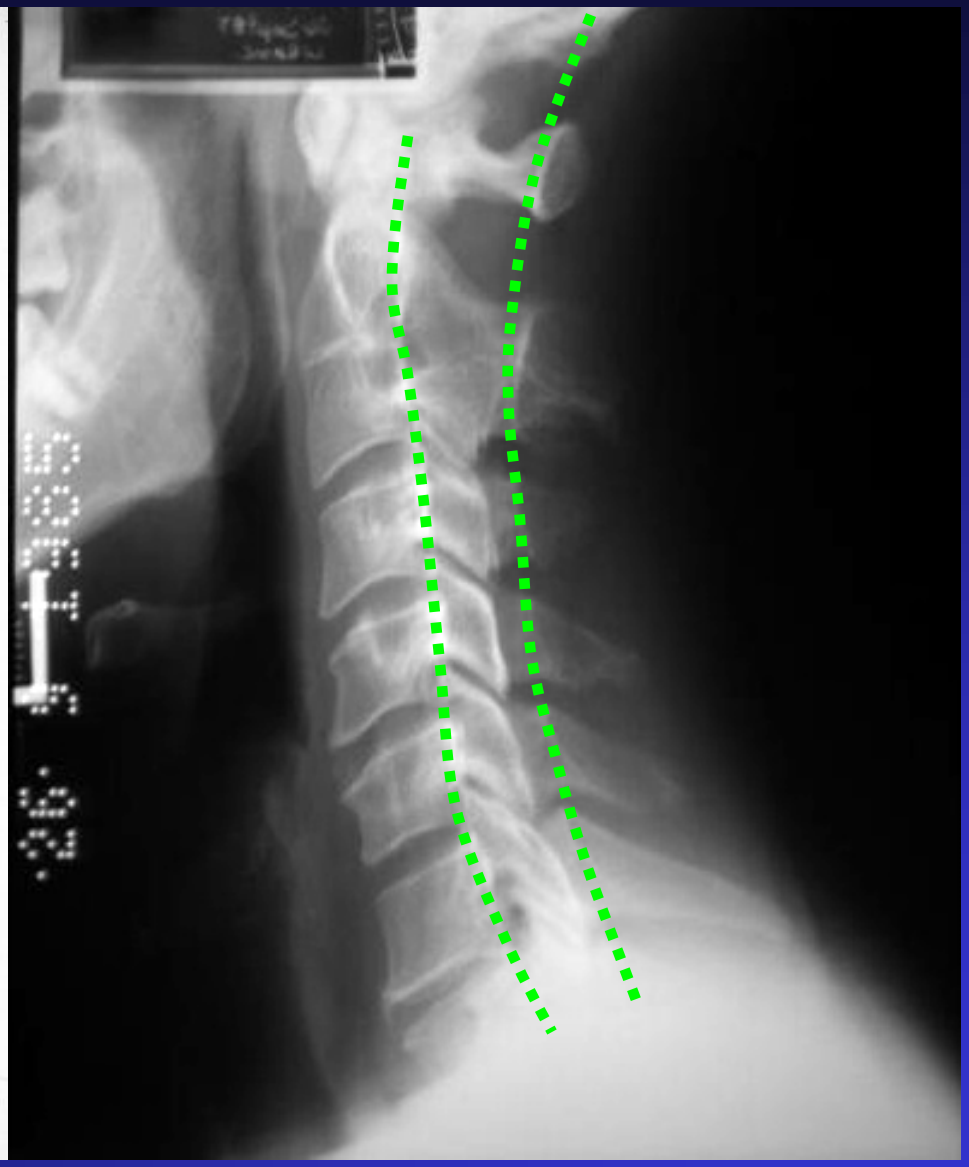

Alignment

Alignment

US
Radiology - http://rad.usuhs.mil

Alignment

Alignment

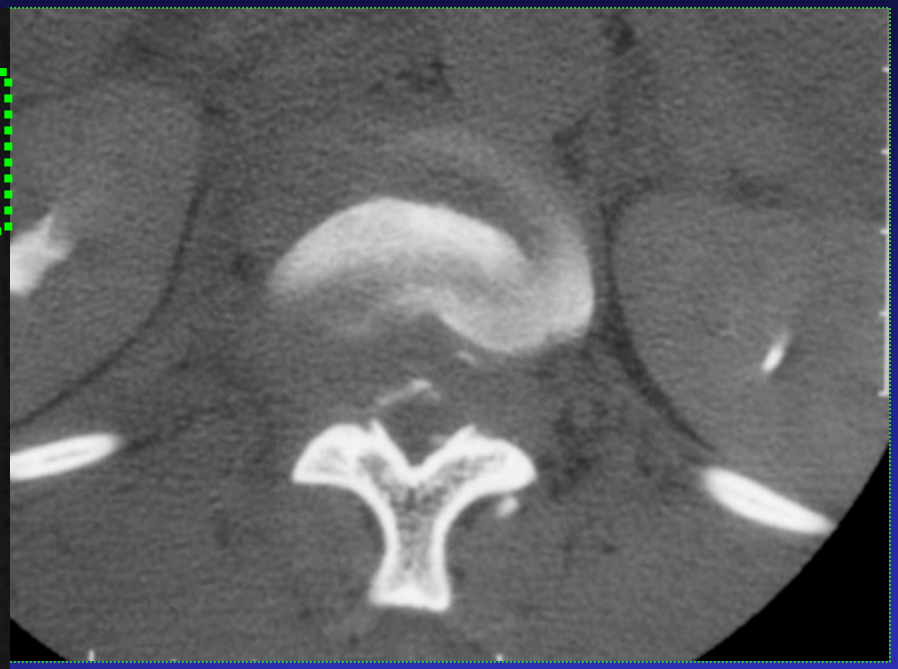

Spine / Back

LIGAMENTS

- Ant. Long. Ligament
- Pos. Long. Ligament
- Ligamentum Flavum
  (Connects Lamina together)
- Interspinous Ligament
  (Connects Spinous processes)

Ligaments and Discs

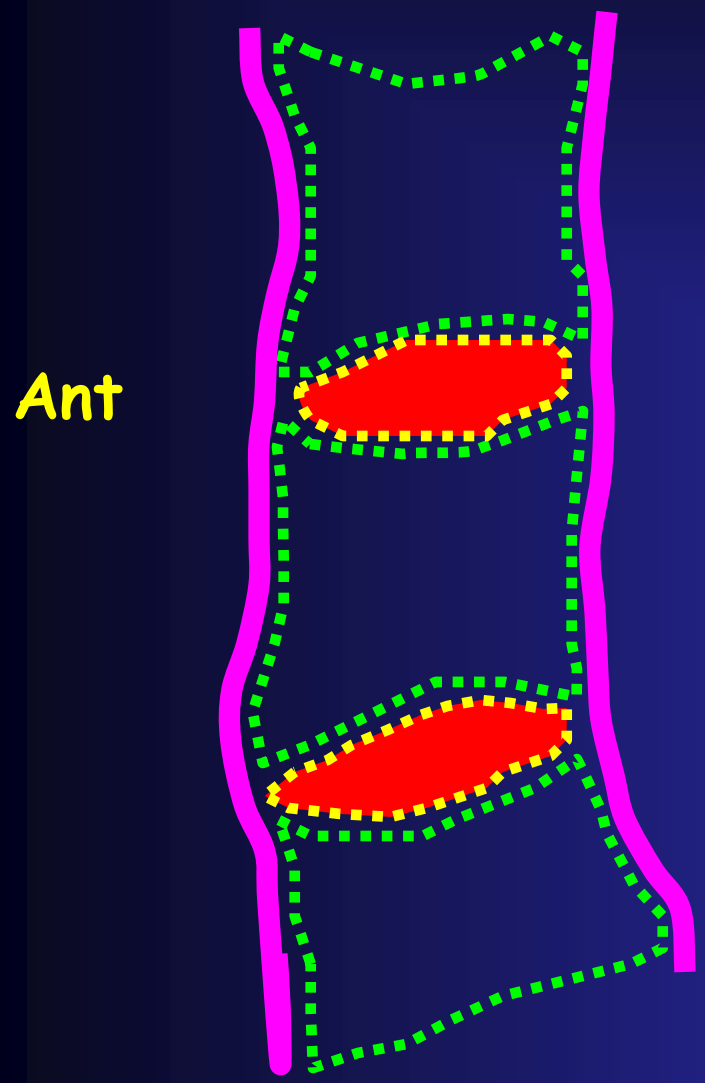

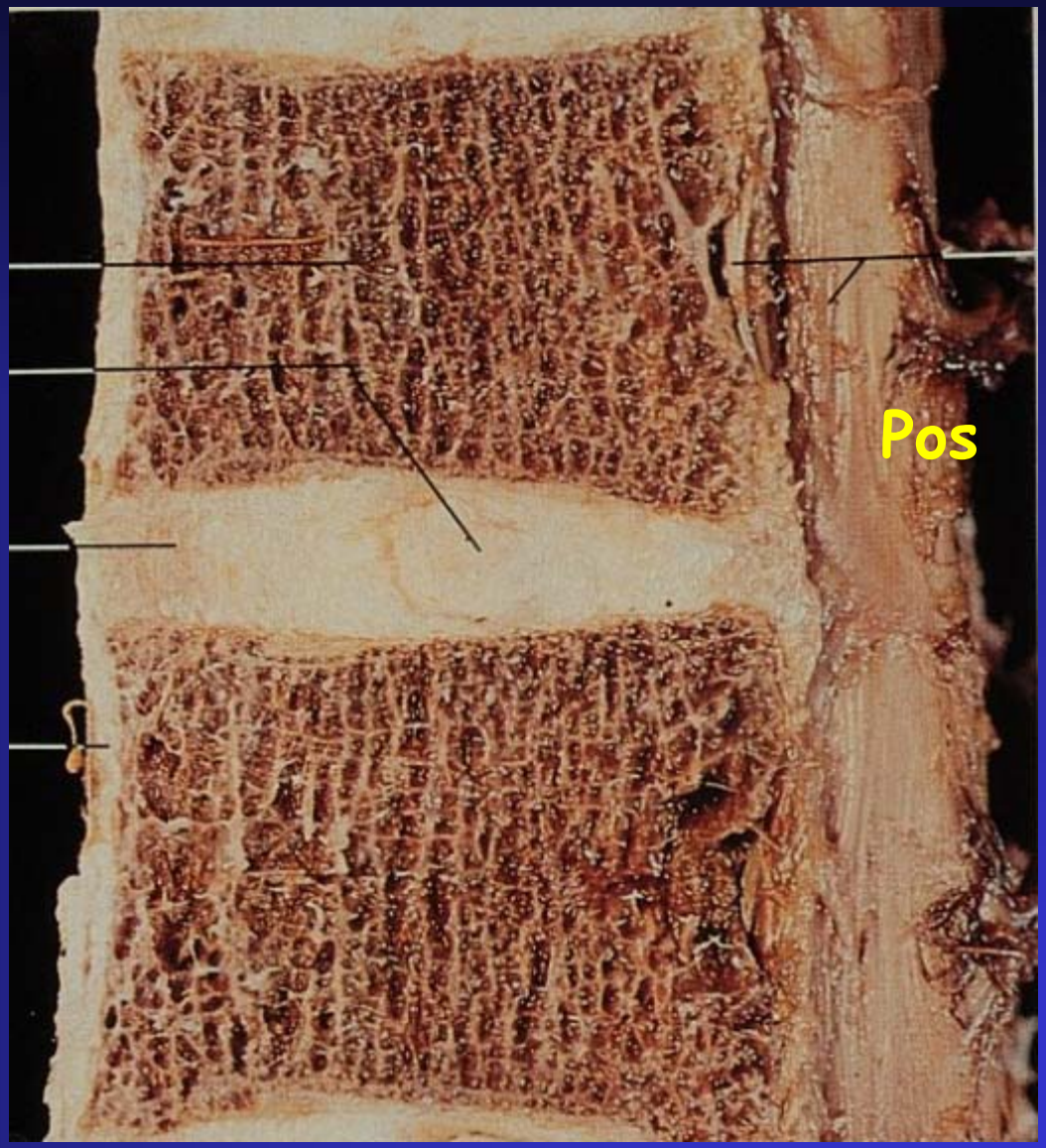

Radiology - http://rad.usuhs.mil

HNP - herniated disc

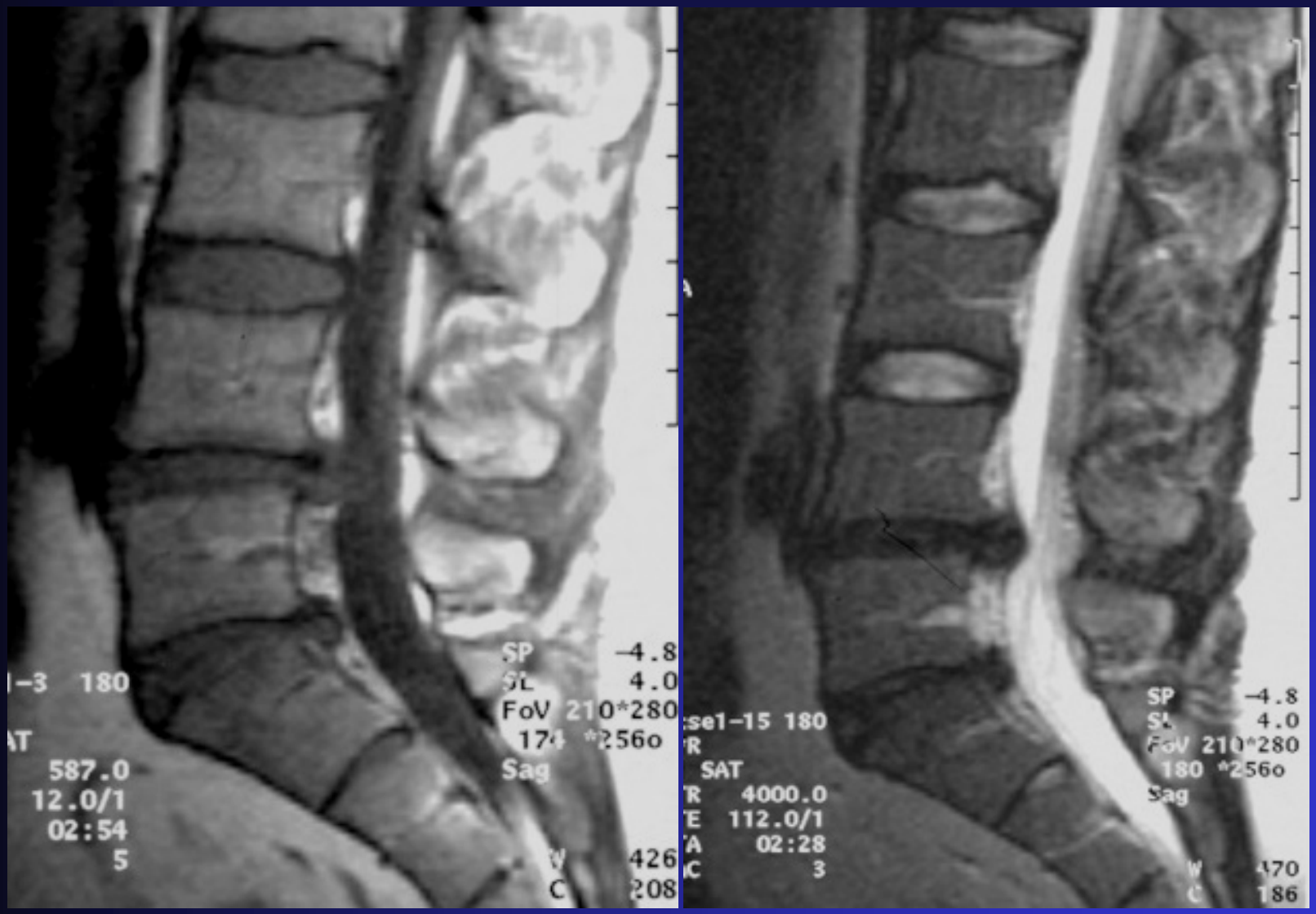

Radiology - http://rad.usuhs.mil

Vertebra - Lat.

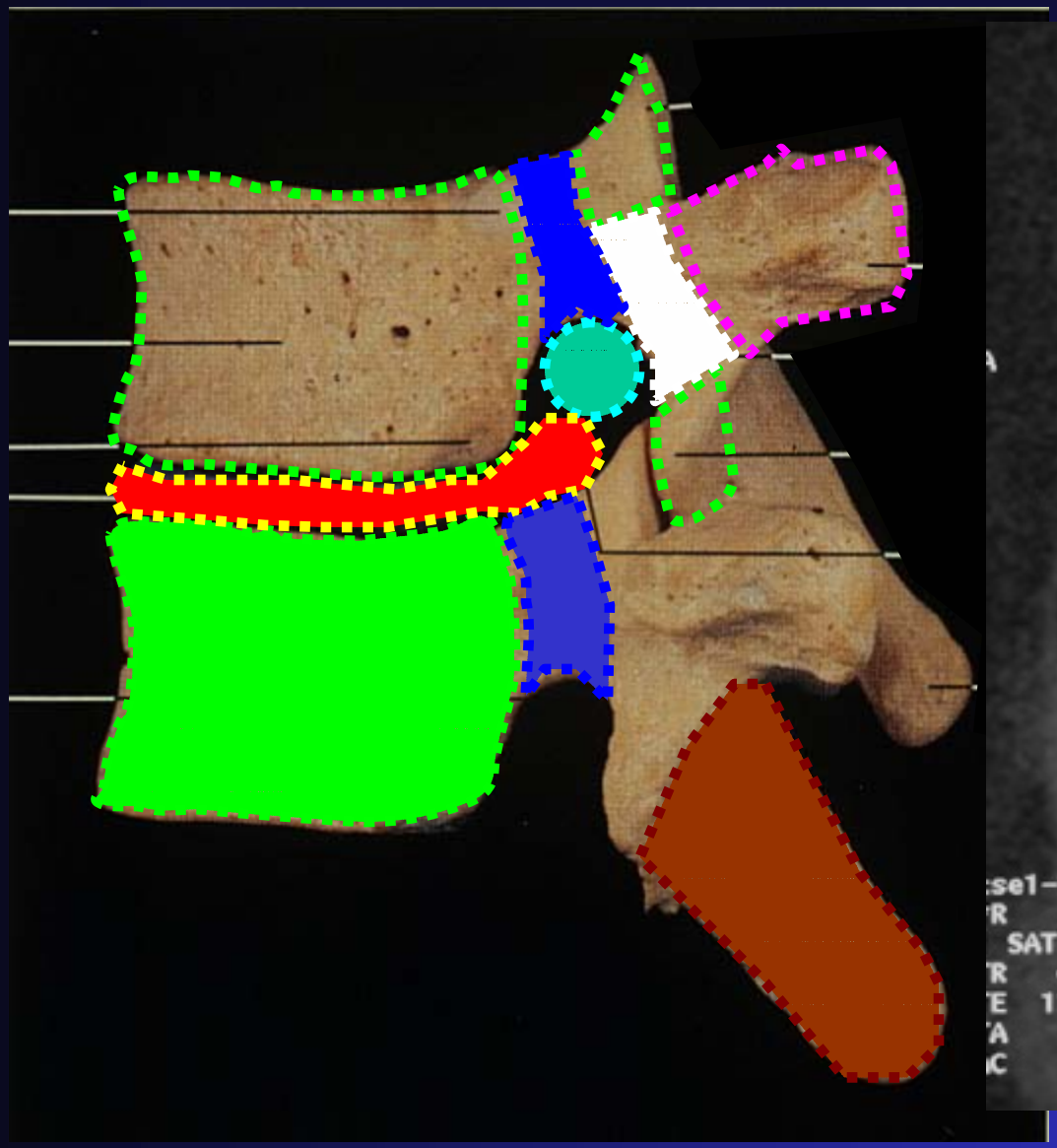

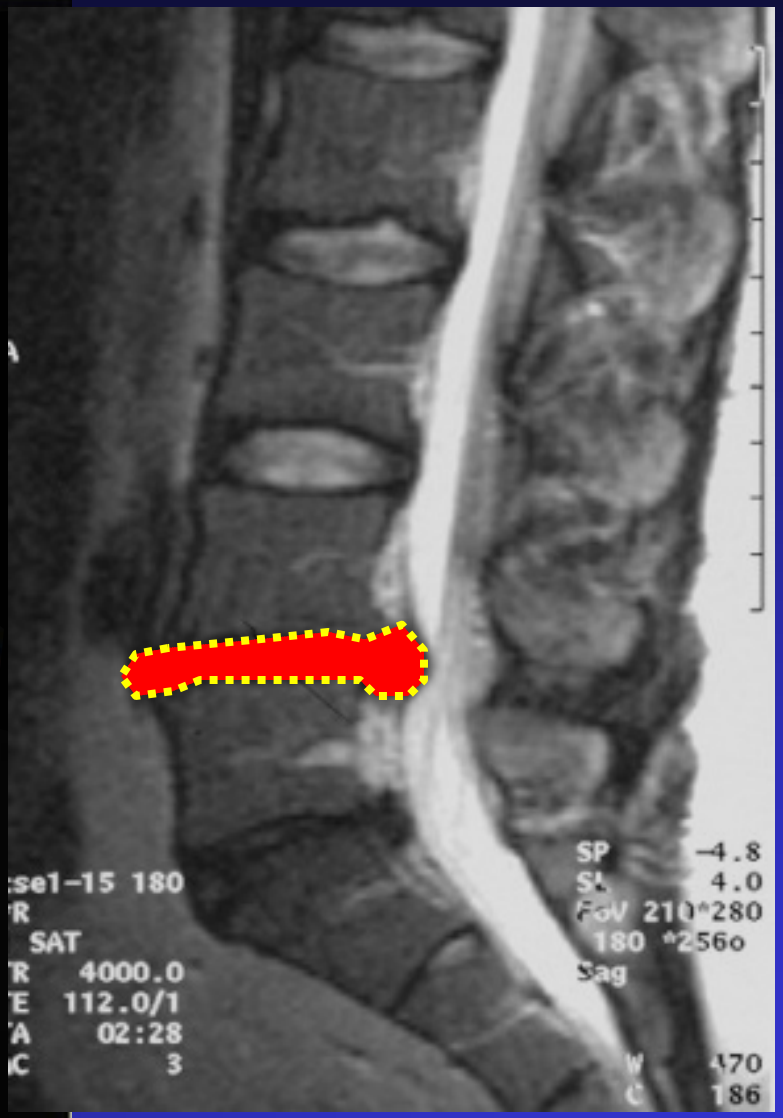

Radiology - http://rad.usuhs.mil

HNP – herniated disc

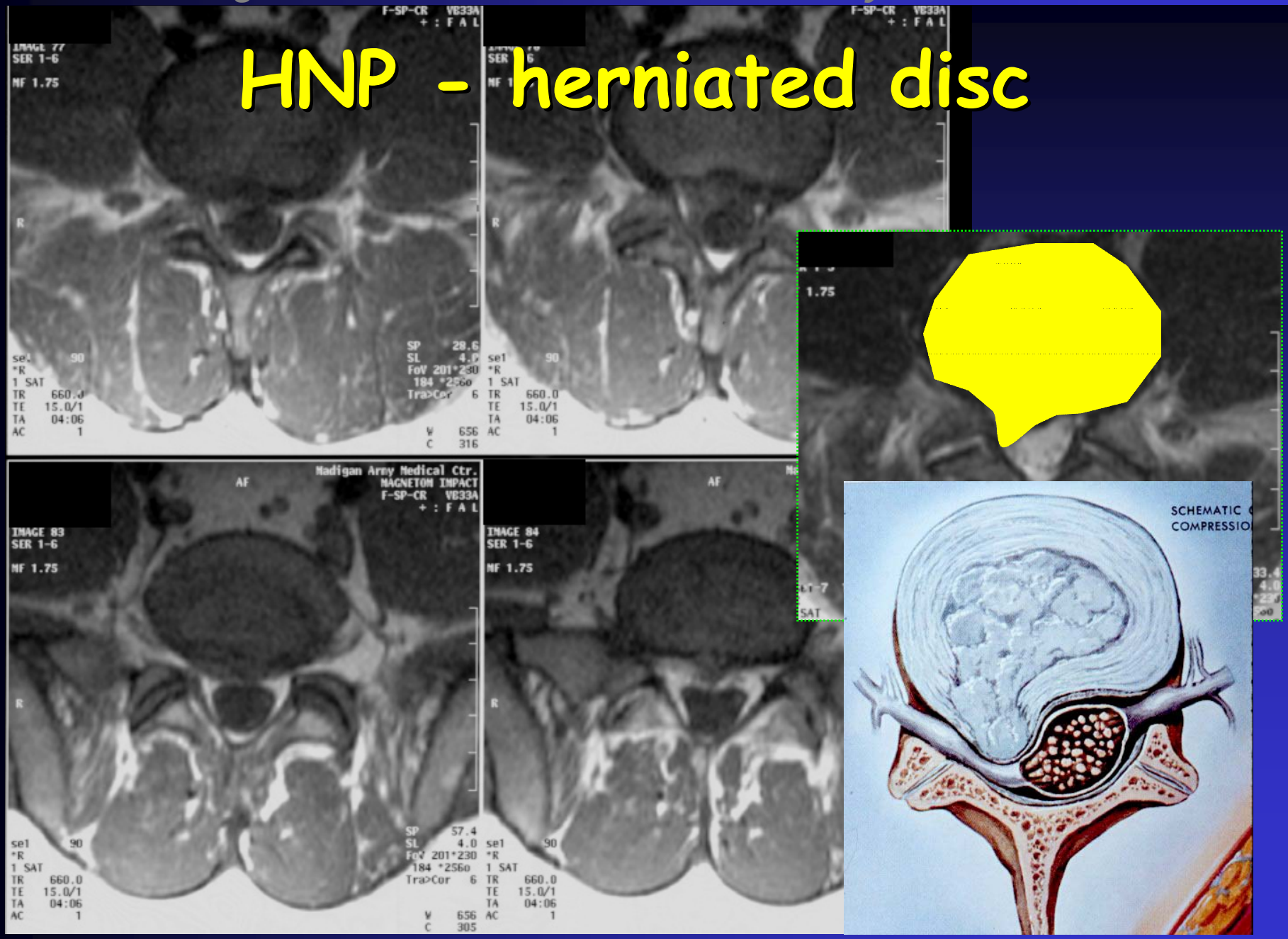

Spine / Back

JOINTS

- Intervertebral Disk
- Facet Joints (lateral masses)
  (Articular Facets)
- Unco-vertebral (body)
  (Uncinate Process - "Hook")

303295
19/SU/
FTF/VFF
+167.5
+7.00
SCALE
F 127.5
92/10/25
10:18:29.1
250MA
140KV
L4
R
L
WL 275
F05

Schwannoma

2
-20.0mm
BCCI
UNI
HOU
367
647
ACQ
14
SE
TR:
TE:
RF:
FOV
TH:
US
192
NSA
6.
REF

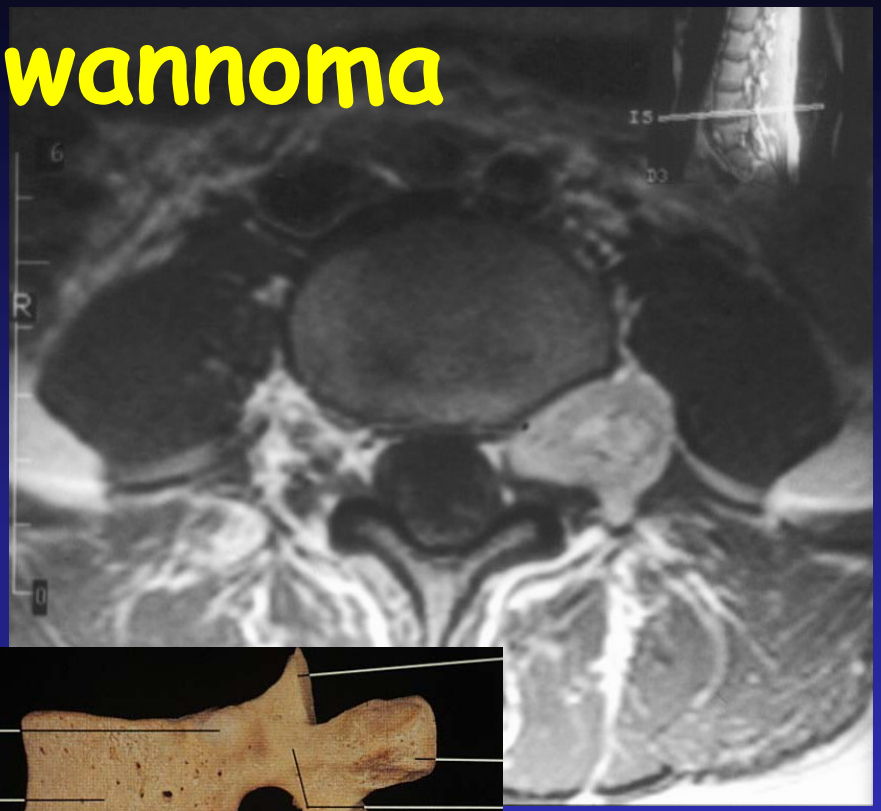

Schwannoma

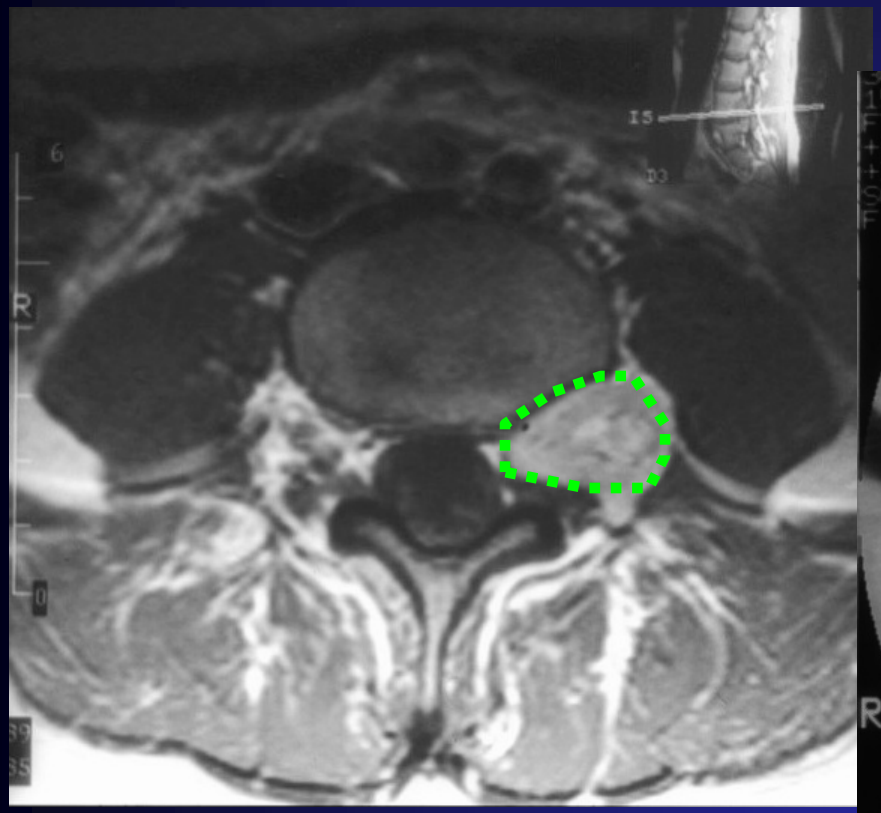

T1W MR

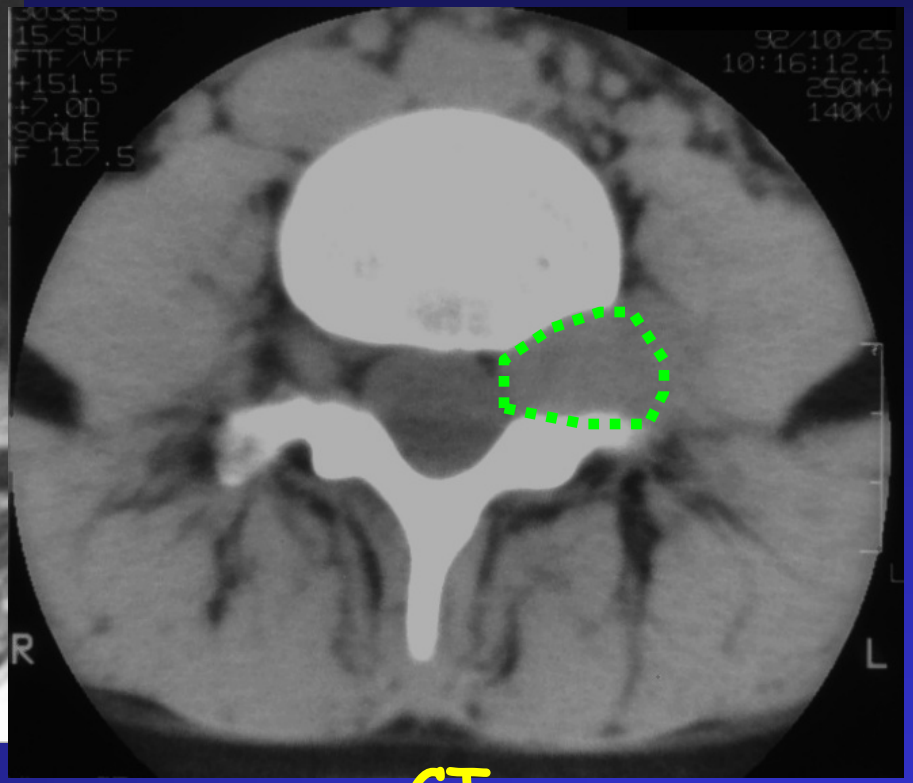

CT

Radiology - http://rad.usuhs.mil

Spine / Back

MYELOGRAPHY

- Lumbar Or Cervical Puncture
- Radiopaque Contrast Injected
- Radiograph and/or CT Images

Cervical Myelogram

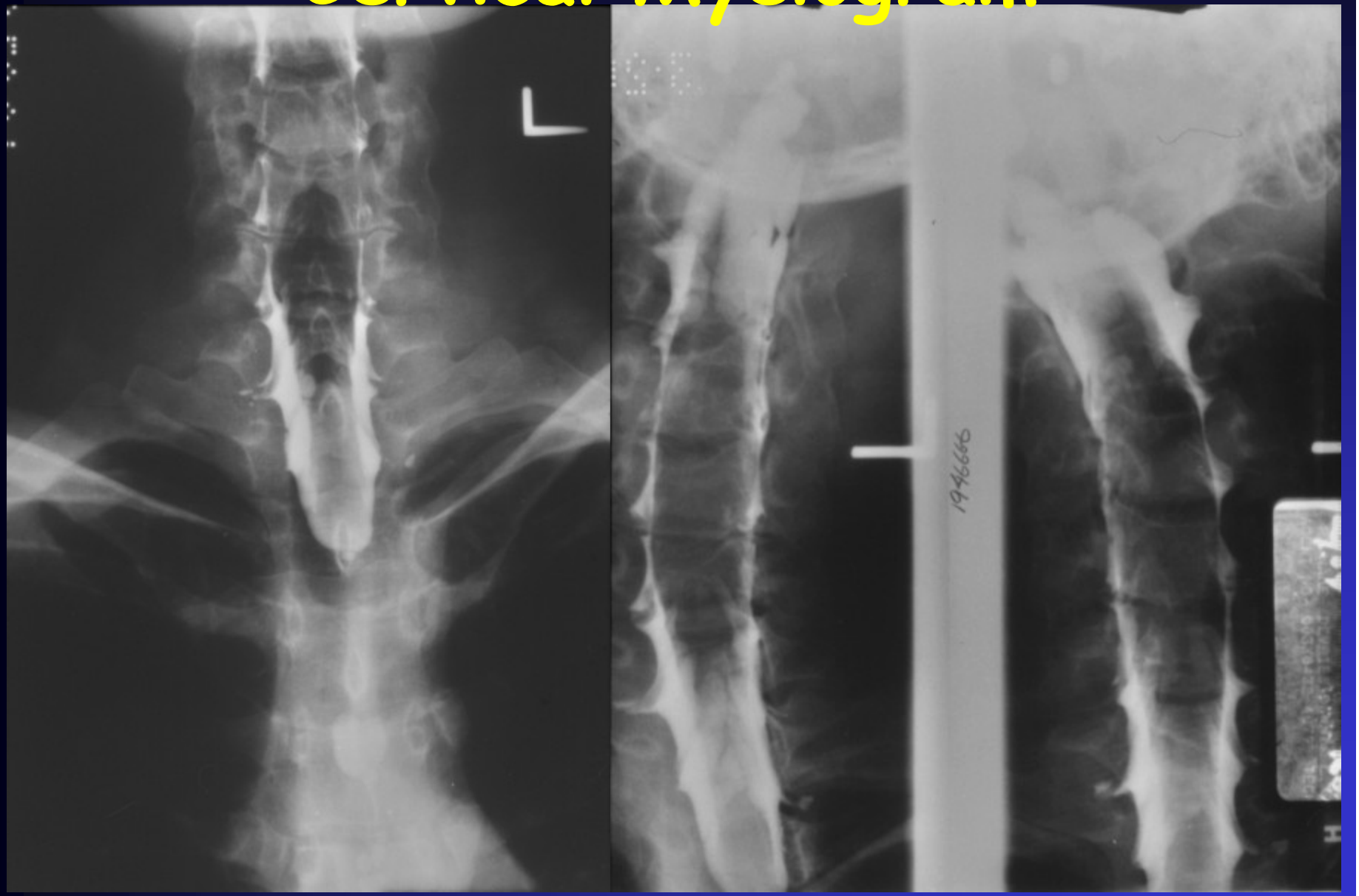

Localization of Spinal Masses

Intra-medullary

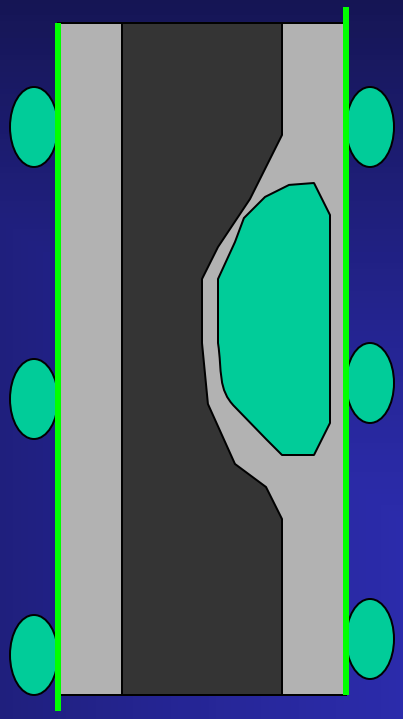

Extra-medullary



Extradural

Spine / Back

Imaging Indications

- Lower Back Pain
- Acute Trauma
- Metastatic / Primary Neoplasms
- Infections (Abscess)
- MS
- Vascular Disease

Shoulder

- Maximum Mobility
- Reduced Stability
  - Dislocation common
- Non-weight bearing
  - Different reactions to Disease

Spine / Back

- Radiographic Studies
  - Plain Film
  - MR Plain/IV Contrast
  - CT Plain/IV Contrast
  - CT / Myelography

Shoulder - Frontal/Coronal

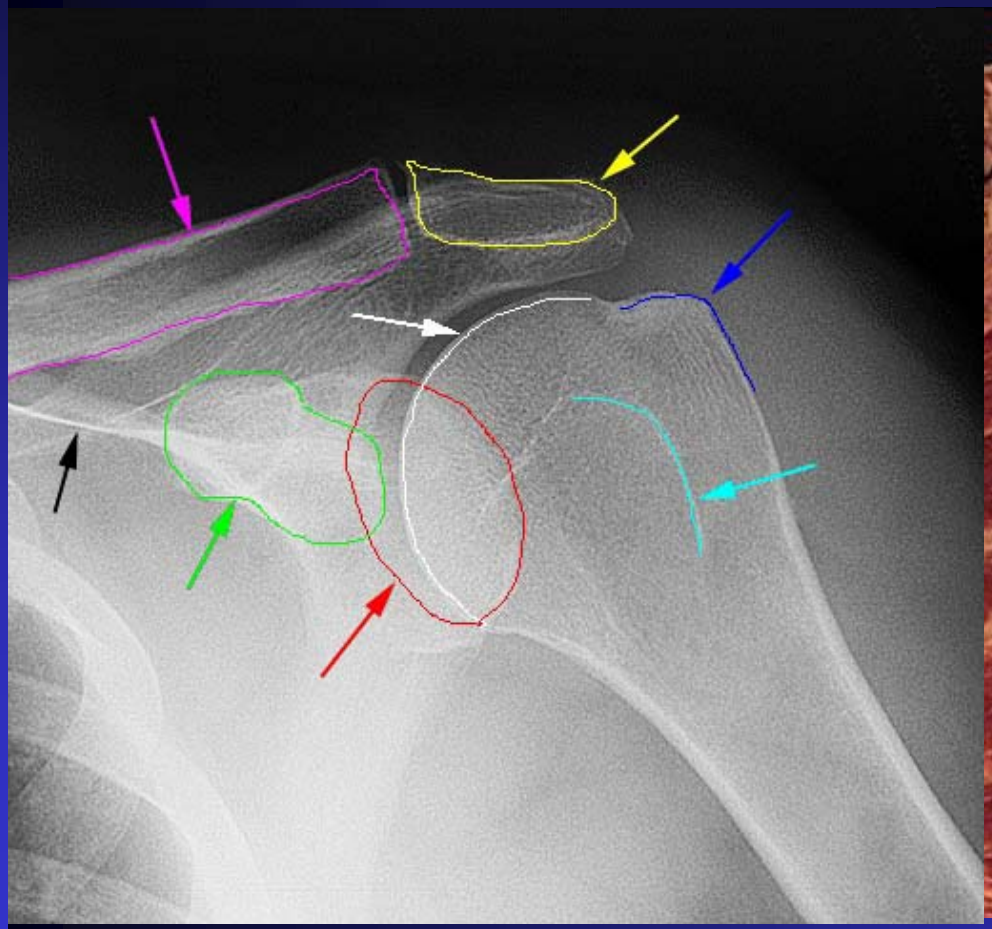

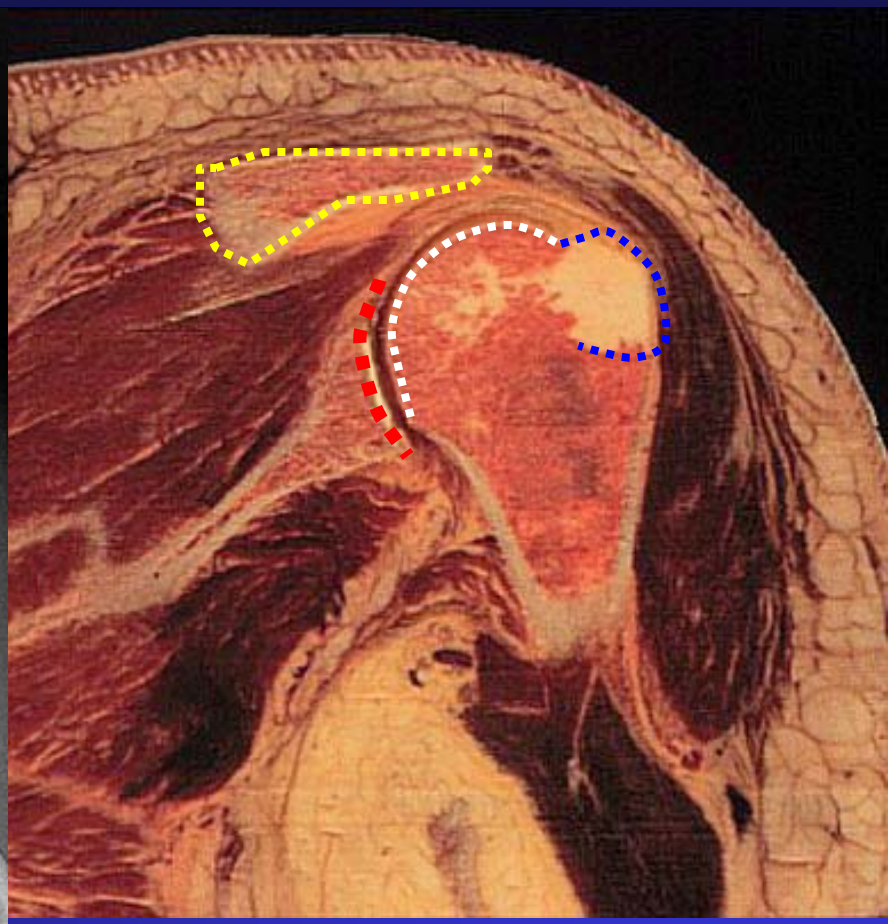

AP Shoulder

External Rotation

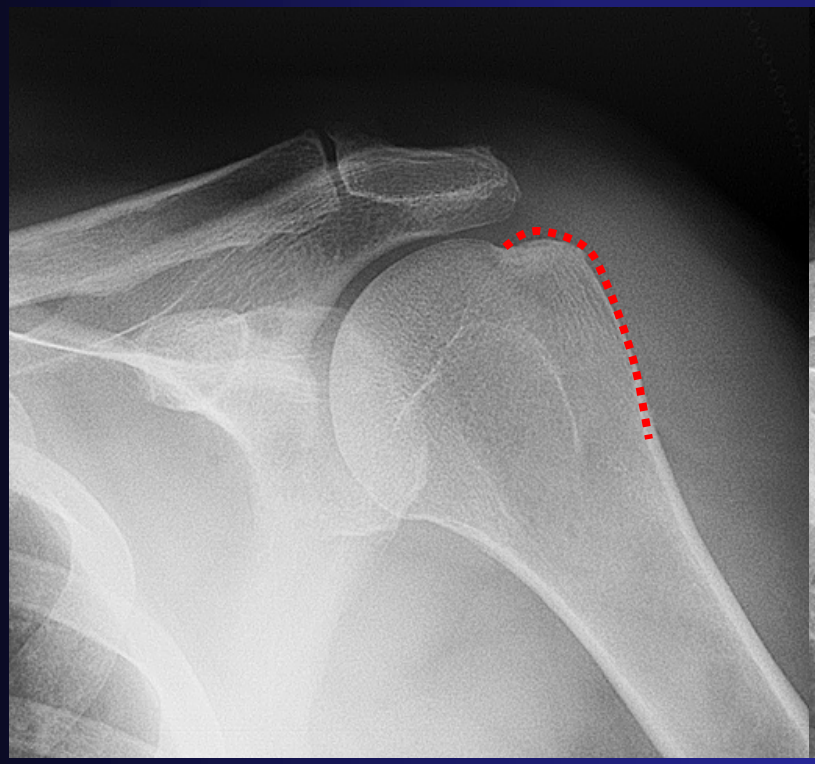

Internal Rotation

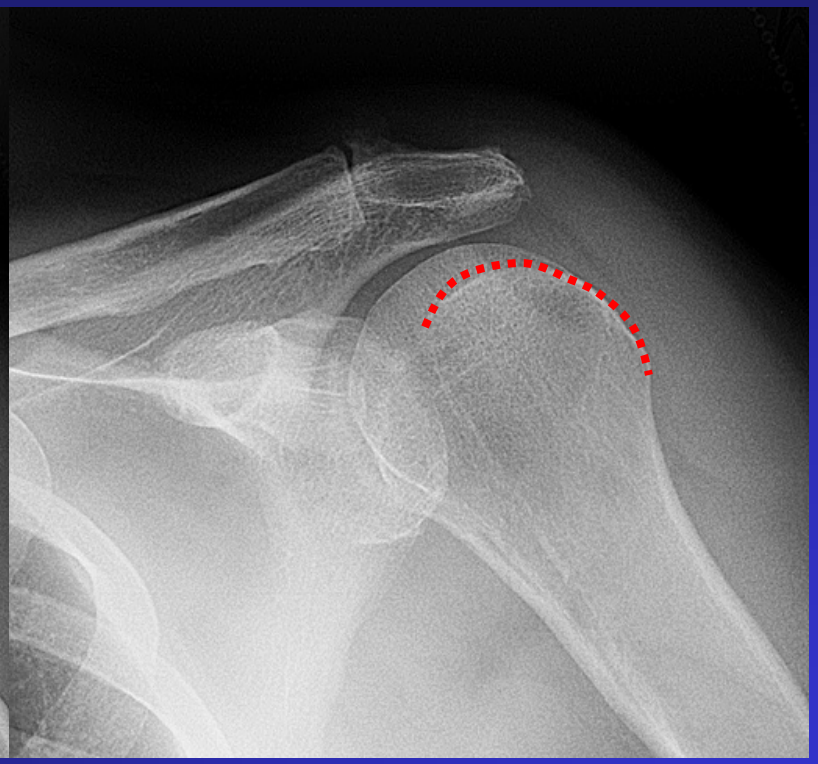

Greater Tuberosity

Coronal Section

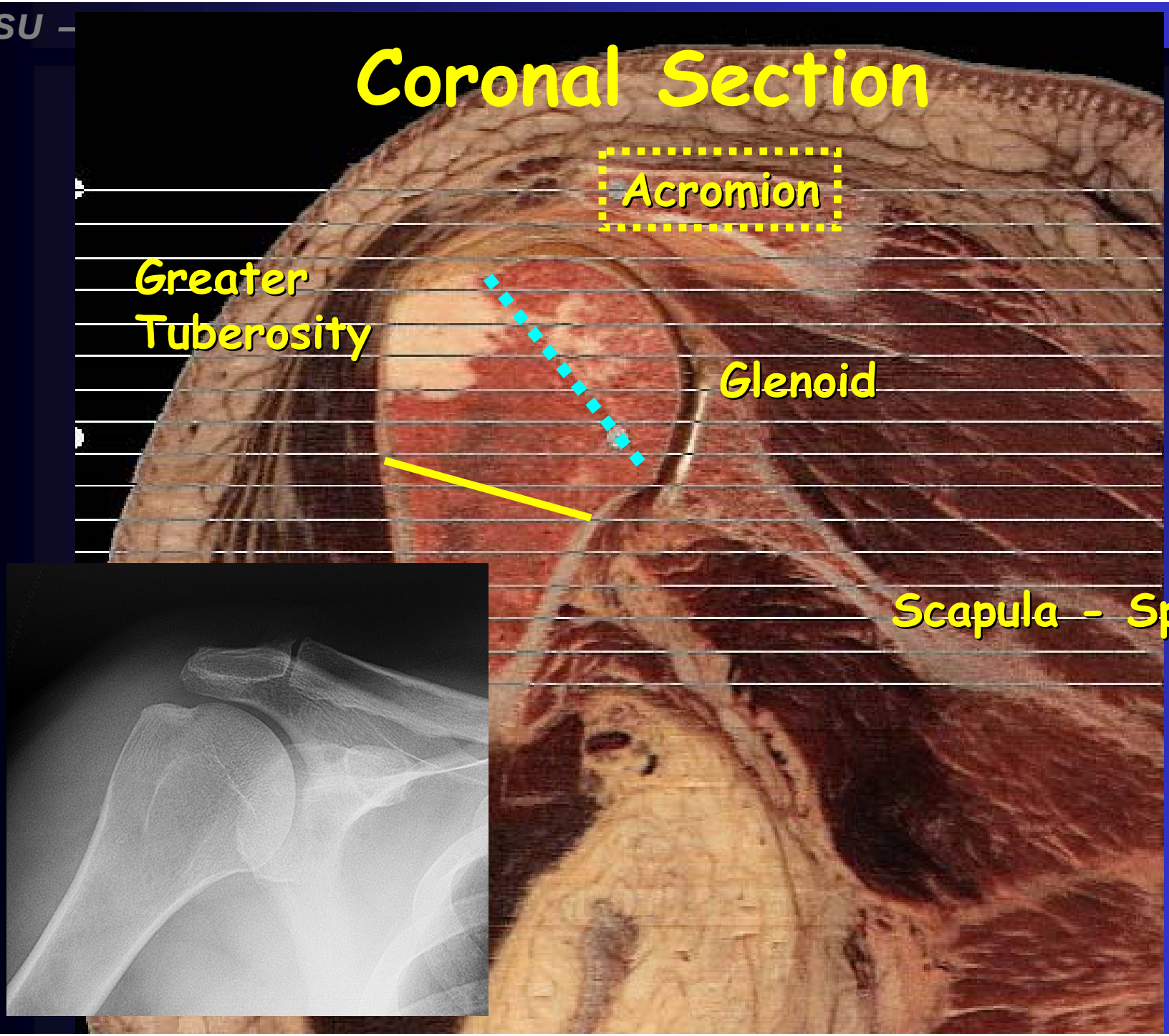

Acropolis = Highest part of City

Smirniotopoulos = Highest part of my bald spot

Coronal Clavicle

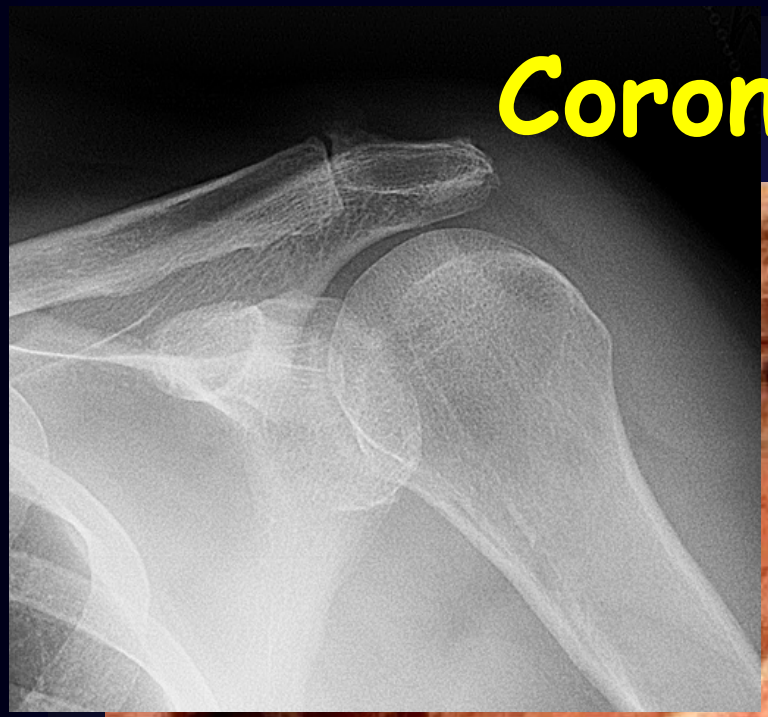

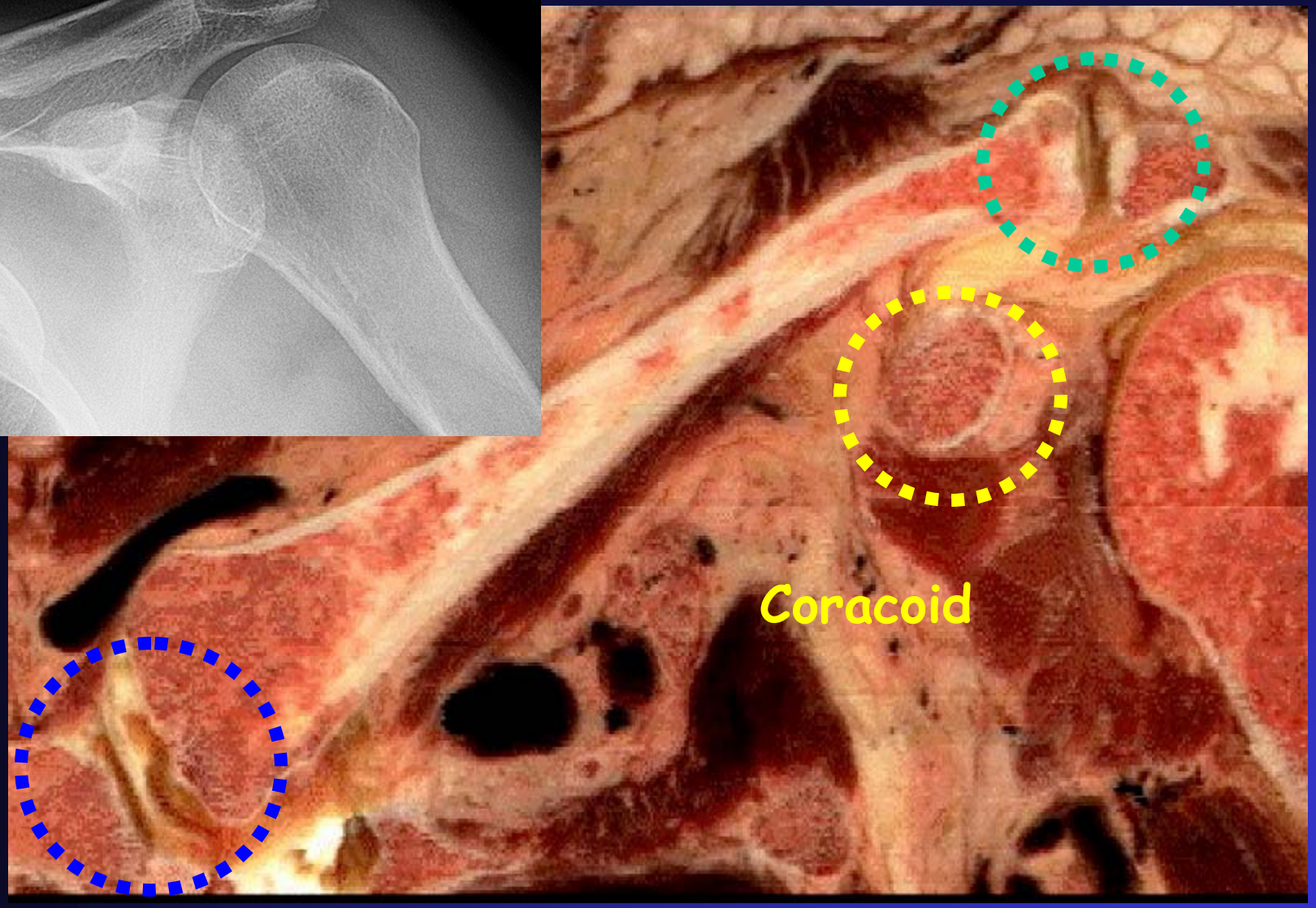

Radiology - http://rad.usuhs.mil

A-C Separation

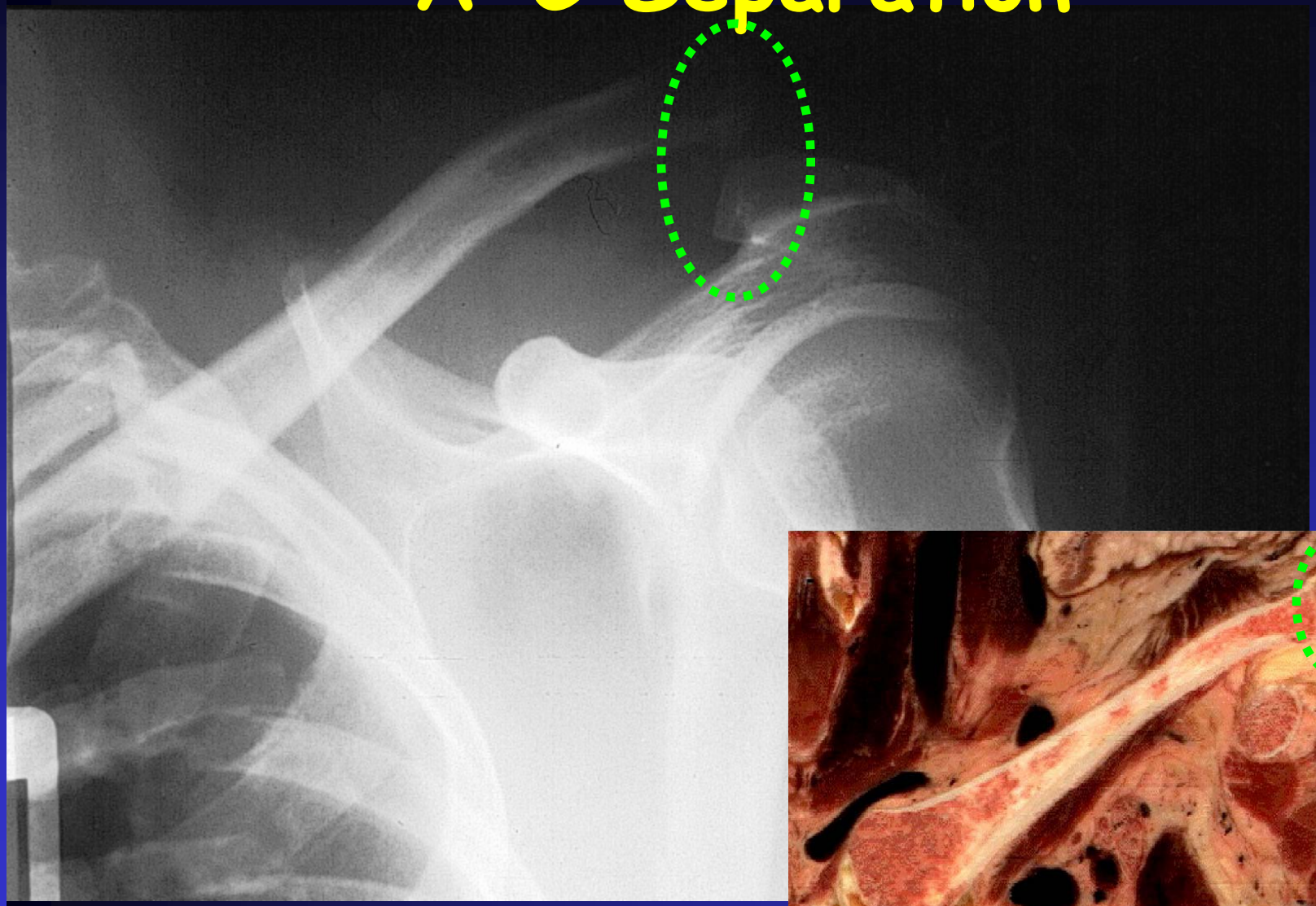

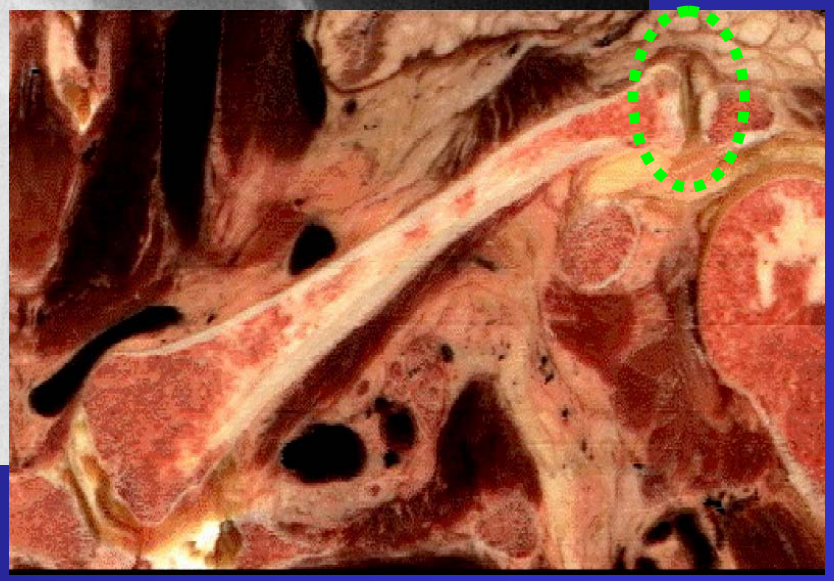

Radiology - http://rad.usuhs.mil

Alignment

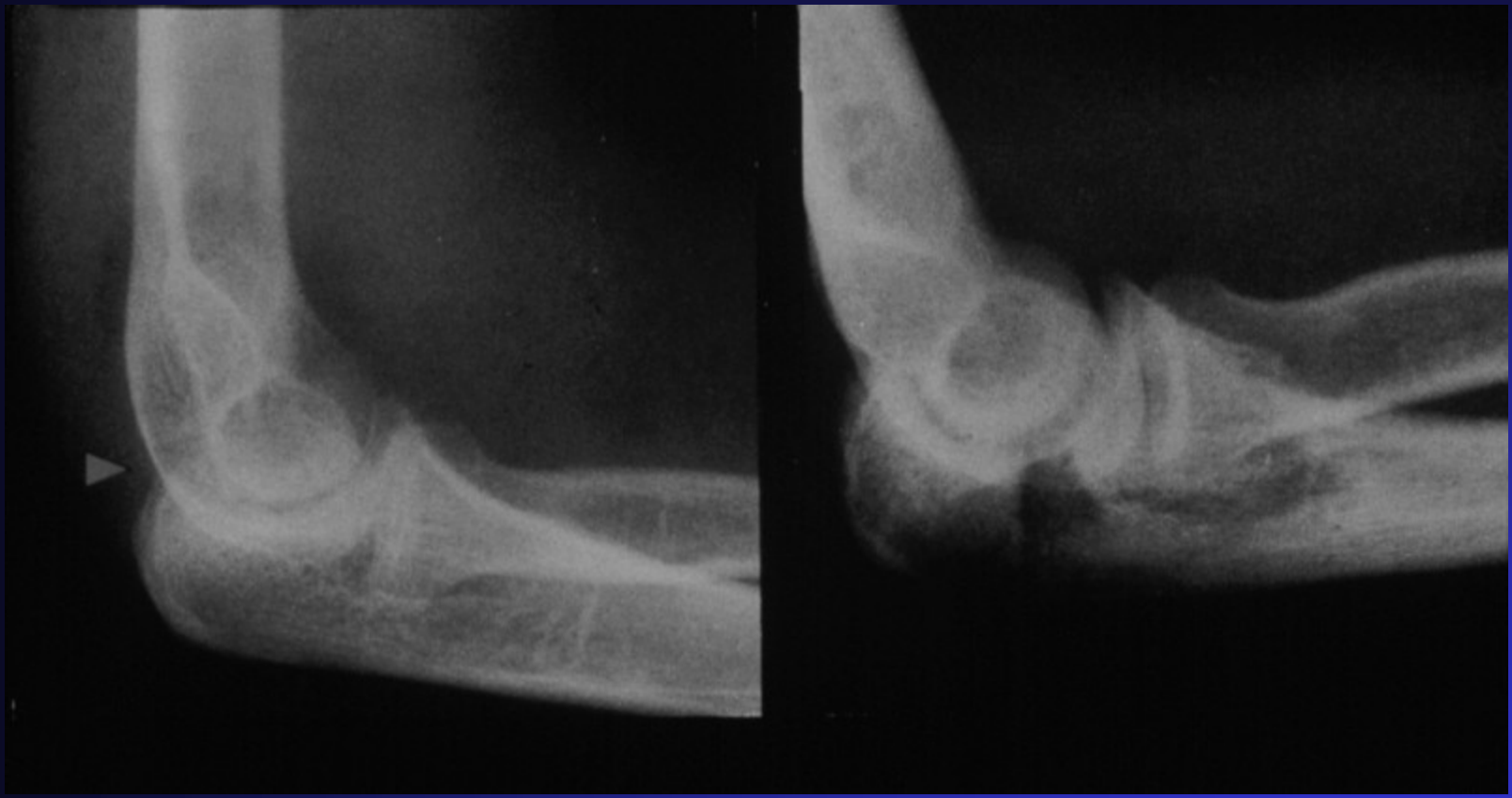

Bone "rings"

Bone Rings

- Must break in TWO places

- Or -

- Must dislocate at joint
- Vertebrae (neural arch)
- Forearm
- Lower Leg
- Pelvis
- Obdurator ring

Bone "rings"

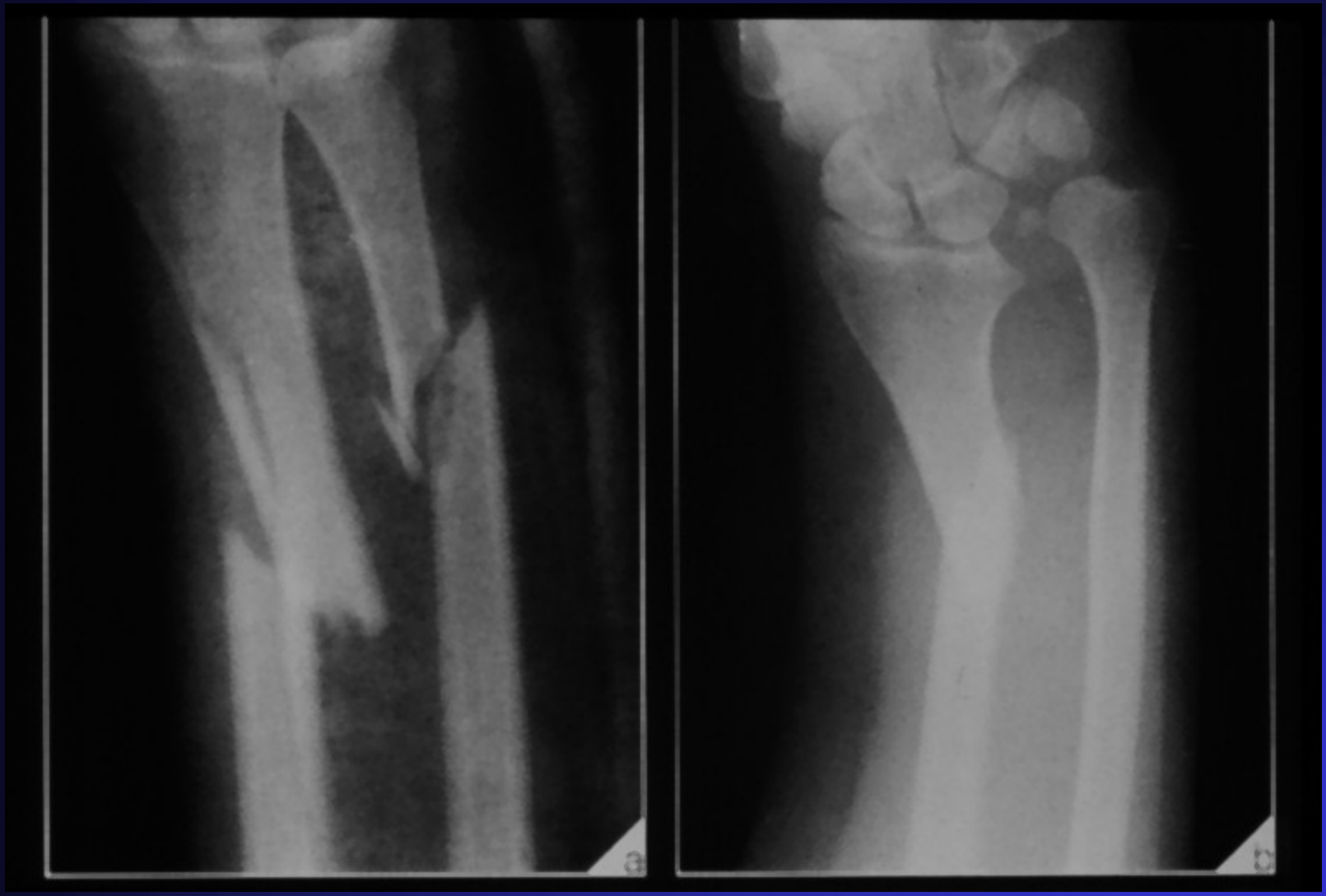

Blood Supply

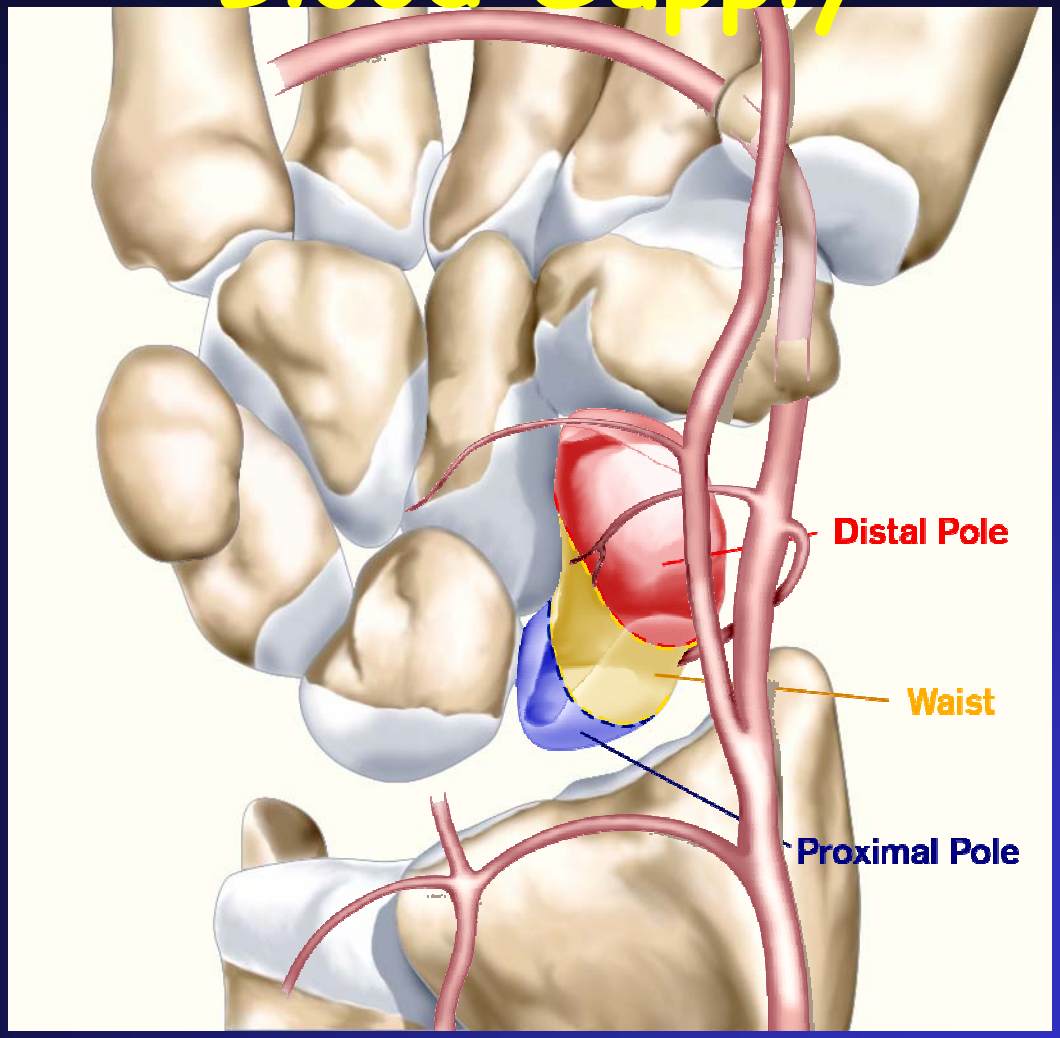

Alignment

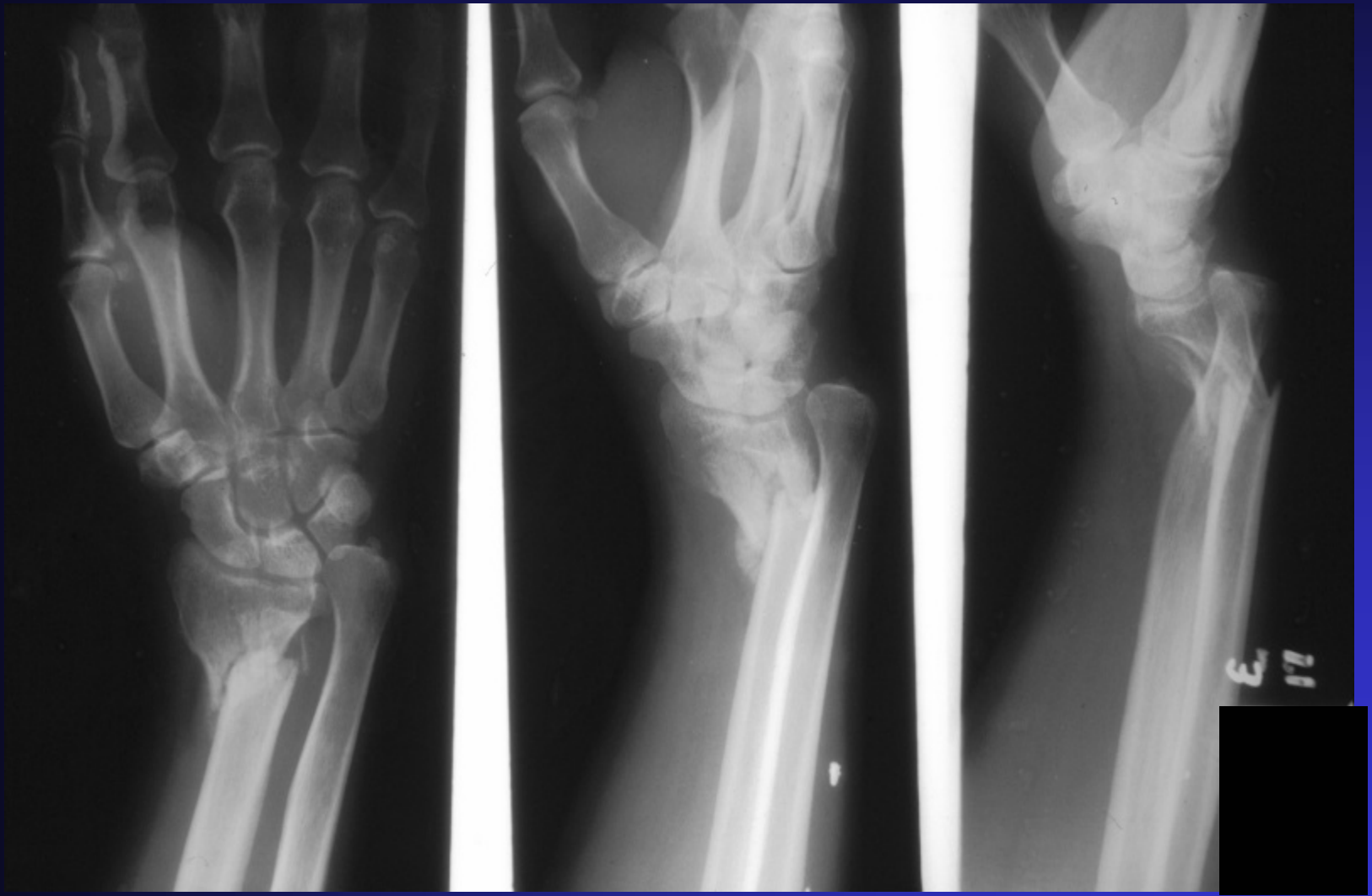

Alignment

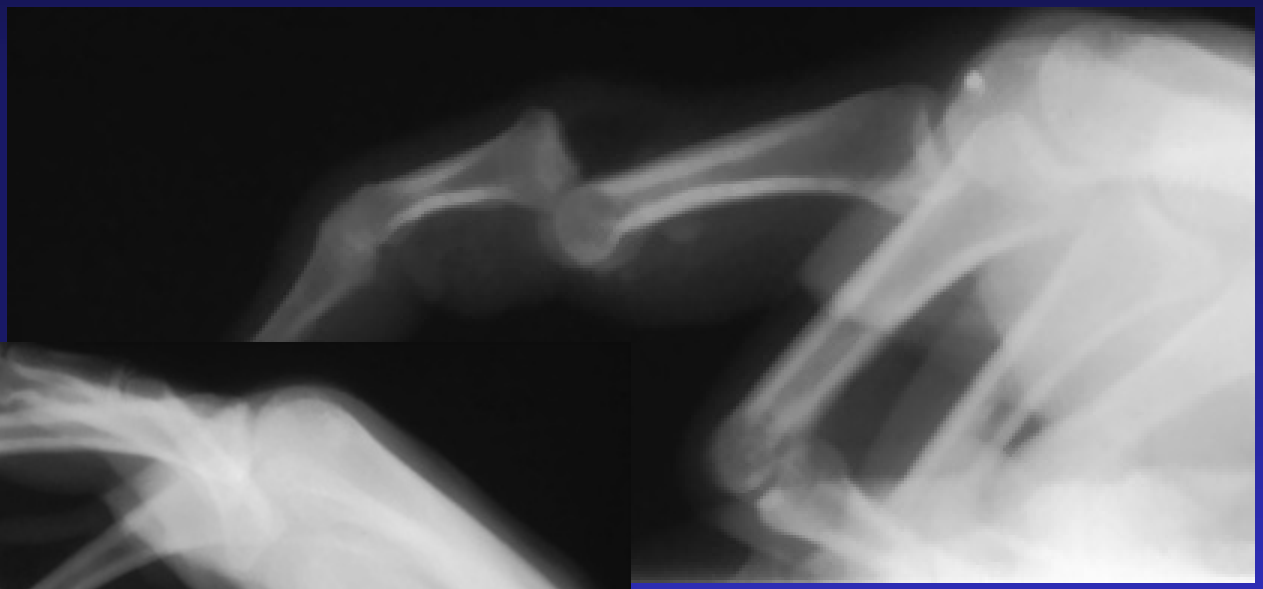

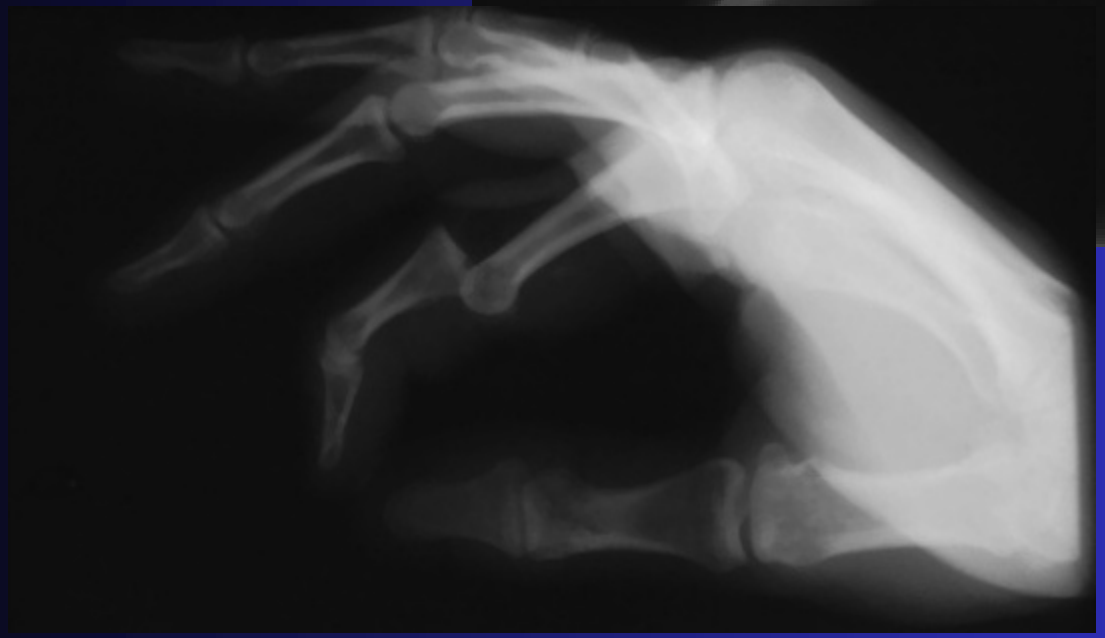

Radiology - http://rad.usuhs.mil

Dislocation

- Complete separation of articular surfaces
- May be associated with a fracture
  - Fracture dislocation

Subluxation

- Part of joint surface remains in contact

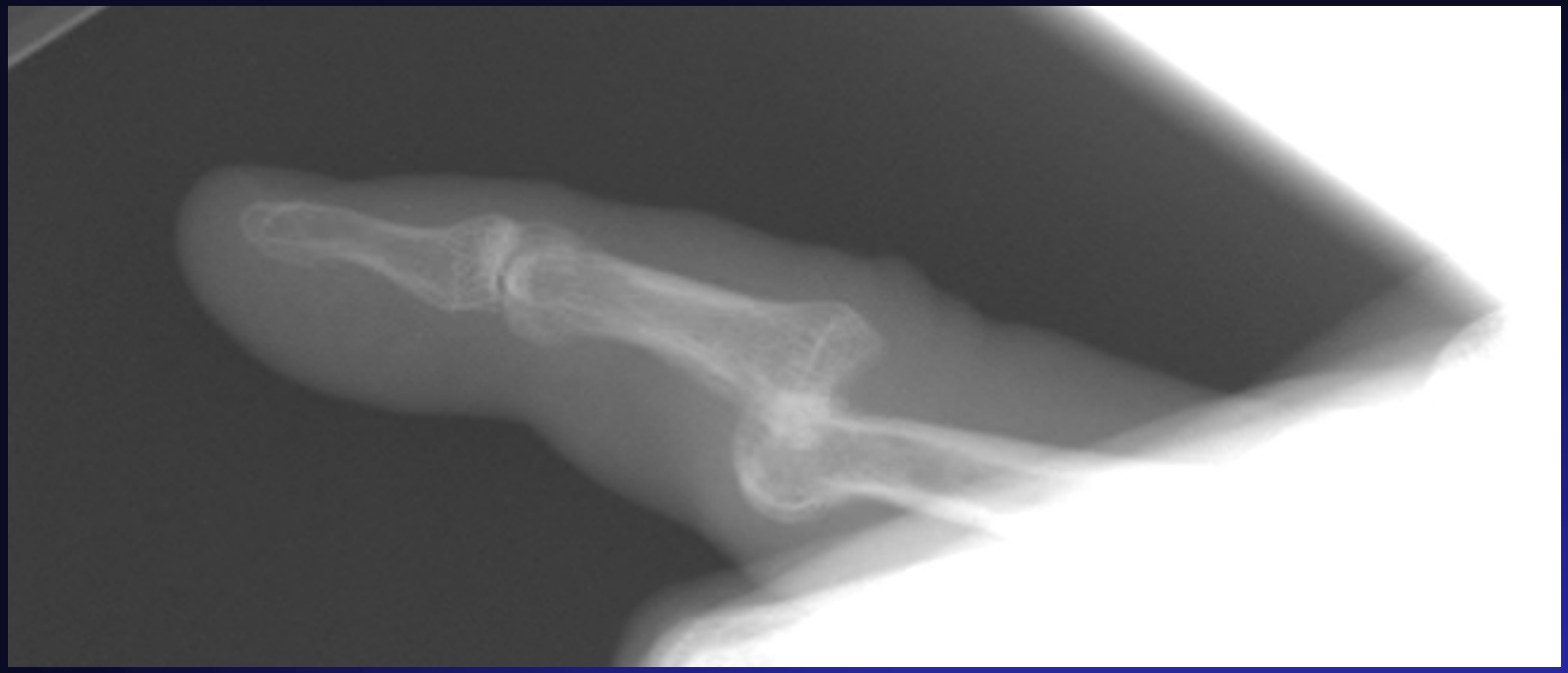

FOUNDATION OF FRACTURE VOCABULARY

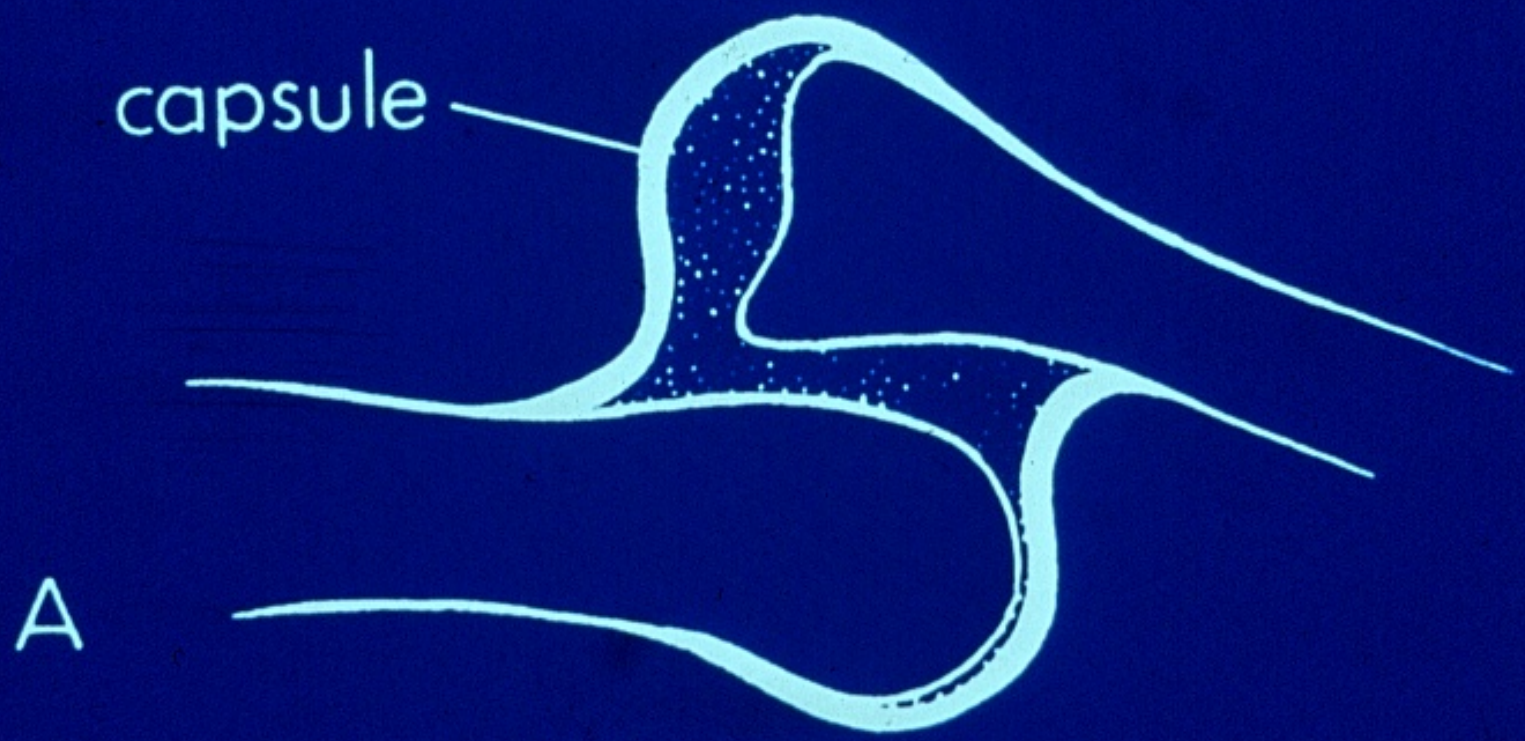

DISEASE CATEGORIES

- **CONGENITAL**
  - DEVELOPMENTAL
  - GENETIC
- **ACQUIRED**
  - TRAUMATIC
  - VASCULAR
  - INFECTION / INFLAMMATION
  - METABOLIC / TOXIC
  - NEOPLASTIC
    - PRIMARY
    - METASTATIC

Size, Shape, Number

Now we count ...