Armed Forces Institute of Pathology

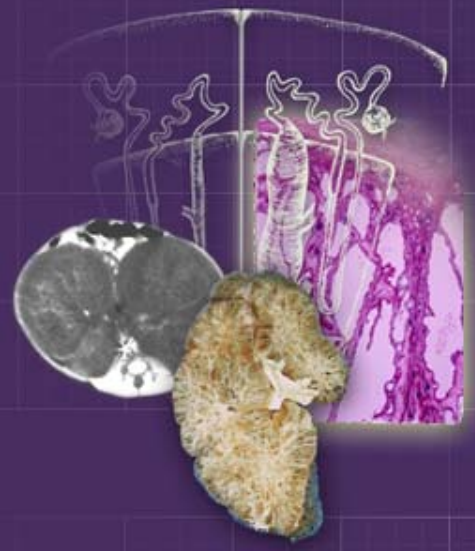

Pediatric Radiology

www.radpath.org

Armed Forces Institute of Pathology

GU Emergencies

Gael J. Lonergan, MD
Associate Professor of Radiology & Pediatrics
Uniformed Services University
Armed Forces Institute of Pathology

GU Emergencies

- Urinary Tract Stone Disease
- Ectopic Pregnancy
- Renal Trauma
- Testicular Torsion

Urinary Tract Stone Disease

- US: 12% of population
- Up to 75% recurrence rate
- Males 3x more commonly affected
- Peak age: 30-50 years
- Low incidence areas:
  - Central & South america
  - Africa

Urinary Tract Stone Disease

- Renal colic: pain of impacted or moving stone
- Stone may impact where ureter narrows:
  - UPJ
  - Crossing over bifurcating iliac vessels
  - UVJ

Urinary Tract Stone Disease

- 90% contain calcium
- Only about 60% of stones are visible on plain film
- Virtually *all* are visible at CT
  - and may be precisely anatomically located

Stone Disease: Imaging

- Plain film: not reliable. Best to eval for other causes of flank pain
- IVP/Excretory urogram: evaluates obstruction from stone
  - Best for ureteral calculi (since these are usually obstructive)
- CT: identifies ~all stones. BEST STUDY
  - But highest radiation

Stone Disease: CT

- Unenhanced (ureteral contrast may simulate stone)
- Rapid - takes ~5 minutes
- Precise anatomic localization
- May detect other pathology:
  - Appendicitis
  - Diverticulitis
  - Adnexal disease . . .

Stone Disease: CT

- Location correlates with likelihood passage:
  - 22% proximal vs. 71% distal
- Proximal stones: ESWL
- Distal Stones: extraction or ISWL
- Size (width) at CT:
  - < 5mm: likely to pass
  - > 7 mm: unlikely to pass

Stone Disease: CT

- Findings:
  - Ureteral dilation
  - Perinephric stranding/fluid
  - Calcification in course of ureter with rim of tissue surrounding (distinguishes from phlebolith)
    - Phlebolith: comet-tail soft tissue adjacent to calcification, central lucency

Ectopic Pregnancy

- 0.2% of all "chemical" pregnancies
- 95% are in fallopian tubes
  - 2.5% uterine cornua
  - remainder:
    - ovary
    - cervix
    - abdomen
- 10-15% all maternal deaths 1st trimester

- Risks:
  - PID
  - Previous ectopic
  - Endometriosis
  - Previous tubal (& pelvic) surgery
  - Infertility & infertility treatments
  - In utero DES exposure
  - Uterotubal anomalies

Ectopic Pregnancy
Presentation

- Abdominal pain
- Vaginal bleeding
- Hypovolemic shock
- May be asymptomatic

- All above typically at 6-8 weeks

Ectopic Pregnancy
Evaluation

- Quantitative beta HCG
- Endovaginal US:
  - Gestational sac
  - Fetal pole (with cardiac activity)
  - Yolk sac
  - Adnexal mass
  - Free pelvic fluid

Ectopic Pregnancy

- In a patient with a positive pregnancy test and abdominal pain or bleeding, find the pregnancy!
  - An IUP makes a coexistent ectopic *extremely* unlikely (1 in 30K pregnancies; 1 in 6-8K assisted pregnancies)
  - Unable to document IUP:
    - Missed AB/demise
    - Anembryonic pregnancy
    - Ectopic pregnancy

Ectopic Pregnancy Evaluation
Guidelines

- 1800 IU HCG (3rd Int Std) or 1000 IU HCG (2nd Int Std):
  - must see gestational sac (endovag US)
- Mean sac diameter (L+W+D/3):
  - >18 mm must have embryo
  - >10 mm must have yolk sac
- 5 mm fetal pole:
  - must see cardiac activity

Ectopic Pregnancy

- No IUP, no suspicious findings; follow quantitative HCG to zero
  - presumptive Dx: “missed’ AB
- No IUP, BUT: adnexal mass/free fluid/symptoms (esp. pain)/worrisome HCG (not falling): consider
  - laparoscopy +/- salpingostomy
  - methotrexate (systemic, intragestational)

"Rule out Ectopic Pregnancy"

- The only way to rule out EP is have a negative pregnancy test!
- EP is highly unlikely if:
  - Patient has IUP
  - Patient is asymptomatic AND:
    - Quant. HCG falling considerably

GU Tract Trauma

- Kidney
- Ureter
- Bladder
- Urethra

Hematuria: Trauma Patients

- Penetrating trauma:
  - all require evaluation
- Blunt trauma requiring evaluation:
  - gross hematuria of >30rbc/hpf
  - microhematuria with shock
  - microhematuria >24hrs
  - high energy impact, multiple organ injury
- REMEMBER: may have significant injury without hematuria!

GU Trauma

- Evaluate lower tract before upper tract if both may be injured
- Males: always perform retrograde urethrogram before foley is inserted if there is blood at the meatus or pubic rami fx/diastasis

Renal Injuries

- Category I - Minor (85%)
  - contusion
  - intrarenal hematoma
  - small subcapsular/perirenal hematoma
  - segmental infarction
  - superficial laceration
- Conservative management

Renal Injuries

- Category II - Serious (10%)
  - deep lacerations
  - laceration through the collecting system
  - large perinephric/subcapsular hematoma
- Conservative management vs. surgery: trend is to more conservative management

Renal Injuries

- Category III - Catastrophic
  - fractured/shattered kidney
  - renal artery occlusion/avulsion
  - renal vein occlusion/avulsion
  - UPJ avulsion
- Usually surgical treatment

Testis Torsion

- torsion of spermatic cord
- bell clapper deformity predisposes
  - abnormally high attachment of tunica vaginalis
  - completely envelops testis/epididymis

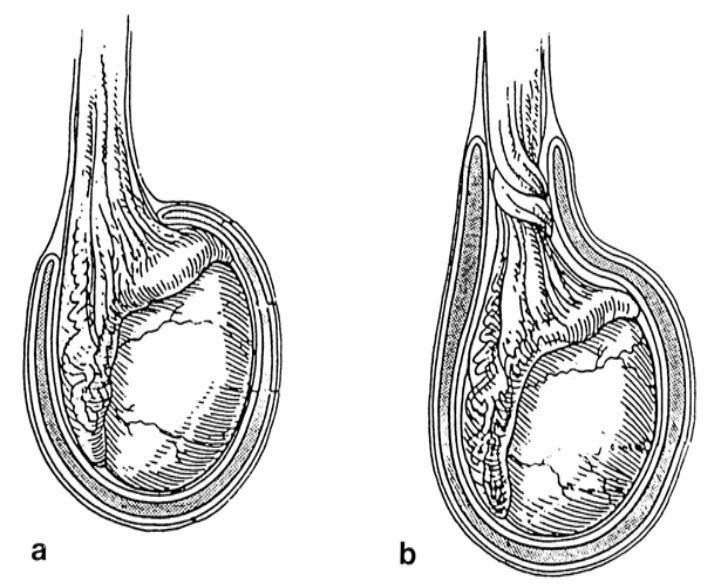

Spermatic Cord Torsion

- all ages (puberty most common)
- severity of ischemia relates to degree and duration of torsion
- salvage rate is < 70% if surgery is > 6 hrs after onset of pain

- may be incomplete
  - venous obstruction > arterial obst.
  - 360° turn < 720° degree < clamping[1]

[1]Palmer JS, et al. J Urol 1997; 158:1140.

- may be intermittent!

Testis Torsion
Presentation

- acute onset painful hemiscrotum
  - nausea, vomiting, fever
- difficulty ambulating
- testis elevated in scrotum & may be in transverse lie[1]

[1]Schulsinger D, et al. J Urol 1991; 145:1053

- involved testis may be larger than asymptomatic testis

Testis Torsion

Imaging: Gray scale Ultrasound

- first 4-6 hours: normal architecture
- becomes heterogeneous & enlarged over next 4-24 hours (worsening appearance correlates with decreased salvagability[1])

[1]Middleton WD, et al. J US Med 1997; 16: 23.

- epididymis & scrotal wall may swell and become hypoechoic
- hydrocele common; non-specific

Testis Torsion

Imaging: Doppler US

- decreased or absent flow is key
- careful comparison with contralateral (normal) testis

US detection of blood flow in the normal testis

- adult & adolescent
  - color: 86-100%
  - power: 100%
  - scint: 80-100%
- prepubertal
  - color: 65-79%
  - power: 69-92%
  - scint: 84-100%

US Evaluation of Possible Torsion

- careful side-to-side comparison
- optimize settings on normal side
- inability to detect flow in normal side renders evaluation inconclusive
  - especially problematic in testis of <1 cc volume

Testis Torsion: Scintigraphy

- diminished distribution of radiopharmaceutical on affected side is key
- early: see less radioactivity on affected side (esp. static images; flow may be normal on angio phase)
- later (6-14 hrs): mild, transient halo
- late (>24 hours): persistent halo

Decisionmaking in suspected testis torsion

- clinical suspicion high: surgery
  - imaging delays treatment (highest salvage when torsion relieved within 6 hours of onset)
- clinical suspicion less certain:
  - color & power Doppler US
  - scintigraphy if US inconclusive
  - explore if both of above inconclusive or either is positive for torsion